

# Regional Conjunctival Differences in Glycocalyx Mucin Expression in Dry Eye and Normal Subjects

Moonjung Choi<sup>1</sup> and Anna Ablamowicz Tichenor<sup>2</sup>

<sup>1</sup>New England College of Optometry, Boston, Massachusetts, United States

<sup>2</sup>School of Optometry, Indiana University, Bloomington, Indiana, United States

Correspondence: Anna A. Tichenor, Indiana University School of Optometry, 800 E. Atwater Ave., Bloomington, IN 47405, USA; [annatich@iu.edu](mailto:annatich@iu.edu).

Received: July 12, 2023

Accepted: January 10, 2024

Published: February 9, 2024

Citation: Choi M, Tichenor AA. Regional conjunctival differences in glycocalyx mucin expression in dry eye and normal subjects. *Invest Ophthalmol Vis Sci.* 2024;65(2):20. <https://doi.org/10.1167/iovs.65.2.20>

**PURPOSE.** To compare regional conjunctival expression of membrane-associated mucins (MAMs) MUC1, MUC4, and MUC16 in normal and dry eye (DE) subjects.

**METHODS.** Adults with and without signs and symptoms of DE were recruited. Impression cytology was performed to collect MAMs from four bulbar and upper eyelid palpebral conjunctival regions of both eyes. After protein extraction, samples from both eyes of a single subject were pooled by region, and expression was analyzed using a capillary electrophoresis nano-immunoassay system. The chemiluminescence intensity of each antigen binding signal was calculated after normalization to the total protein amount. Statistical analyses were conducted using GraphPad Prime 9.

**RESULTS.** Samples from thirteen to sixteen DE and seven to eleven normal subjects were analyzed. In normal samples, MUC1 expression from the nasal bulbar conjunctiva was significantly greater than superior ( $P = 0.004$ ) and inferior ( $P = 0.005$ ). In DE samples, MUC1 expression was highest superiorly. Significant differences in MUC4 and MUC16 expression were not seen in normal samples. MUC4 and MUC16 expression was upregulated superiorly ( $P < 0.0001$ ) and inferiorly ( $P < 0.0001$ ) in DE compared with those regions in normal samples.

**CONCLUSIONS.** Although MAMs form a hydrophilic barrier called the glycocalyx, each mucin may have unique functions that are currently unexplored. All MAMs were expressed in the upper palpebral conjunctiva. Increased MUC1 expression nasally in healthy subjects suggests a functional need for increased protection. When comparing DE with normal eyes, upregulation of MUC1 superiorly, and in both MUC4 and MUC16 both superiorly and inferiorly, may indicate a need to decrease eyelid friction during blinking, especially in DE.

Keywords: dry eye, glycocalyx, membrane-associated mucin, MUC1, MUC4, MUC16, lid wiper

The ocular surface is a unique, wet-surfaced epithelium exposed to the environment, making it highly susceptible to injury, pathogens, and dryness. Consequently, the eye uses various biological mechanisms and structures to safeguard and moisturize itself, ensuring a transparent cornea and a water-loving surface that are crucial for maintaining clear vision. All wet-surfaced epithelia, including the eye, are covered by a mucous coating known as the glycocalyx. The glycocalyx functions to protect the ocular surface by serving as a barrier against pathogens and to create a hydrophilic surface for tear film adherence and coverage to maintain ocular lubrication. The glycocalyx is composed primarily of membrane-associated mucins (MAMs), known as MUC1, MUC4, and MUC16.<sup>1,2</sup> These mucins are also present in the tear film, with MUC5AC being the primary gel-forming mucin secreted into the tears.<sup>3</sup> Its primary functions are to trap allergens, clear away debris, and form a mucus gel tear film for optimal hydration. Goblet cells, which produce these mucins, are most numerous in the lower fornix and lower palpebral region to aid in trapping debris found in the tear film.<sup>4</sup> They have also been detected in the palpebral conjunctiva of the lid margin of the eyelids.<sup>5</sup>

MAMs such as MUC1, MUC4, and MUC16 are expressed in both the cornea and conjunctiva.<sup>6,7</sup> However, the distribution of MAM expression across different regions of the conjunctiva is unknown, although it is known that the mRNA level for MUC4 decreases toward the central cornea.<sup>8</sup> Similar variations in MAMs expression exist in other parts of the body, such as the lung epithelia, where they contribute to formation of a mucin mesh network that effectively repels bacteria and unwanted particles in the airways.<sup>2,9</sup> Furthermore, a study by Gipson et al.<sup>10</sup> compared the functions of MUC1 and MUC16 on the eye, and determined that knockdown of MUC16 decreased corneal epithelial cell barrier function in vitro, whereas knockdown of MUC1 did not have the same effect on barrier function. Others have shown that MUC1 plays a significant role in modulating pathogen-induced inflammation in gastric mucosa, suggesting differences in mucin function despite their similar underlying structures.<sup>11,12</sup>

Dry eye disease (DED) is a multifactorial ocular surface disease characterized by an imbalance in tear film homeostasis, leading to tear film instability, hyperosmolarity, ocular surface inflammation and damage. Notably, goblet cell loss

and decreased MUC5AC levels are often observed in moderate to severe DED.<sup>13–15</sup> However, studies investigating the effects of DED on MAMs show inconsistent results likely owing to the complex etiology and highly variable severity levels of DED as well as different techniques used for *in vivo* sampling.<sup>16–21</sup> Kessing<sup>22</sup> established the differences in goblet cell density in the bulbar conjunctiva of the eye in 1968. Impression cytology, a technique first described by Egbert et al.<sup>23</sup> in 1977, is used to study goblet cells in the conjunctiva. Therefore, impression cytology can also be used to collect conjunctival epithelial cells *in vivo* for the analysis of MAM expression. It is hypothesized that there may be some initial compensatory increases in MAM expression during the early stages of DED, but in severe disease and subsequent damage to ocular surface tissues, decreased MAM expression becomes evident. To test this hypothesis, the variation in conjunctival expression of MAMs must be investigated in individuals without DED and then compared regionally in DED.

The aim of this study was to evaluate whether the palpebral conjunctiva in the lid margin of the eyelids expresses MAMs and compare MUC1, MUC4, and MUC16 expression across different areas of the bulbar conjunctiva in patients with and without DED. The anatomical regions of the bulbar conjunctiva investigated included the nasal, superior, inferior, and temporal regions.

## METHODS

### Subject Selection

This research was reviewed by an independent ethical review board and conforms with the principles and applicable guidelines for the protection of human subjects in biomedical research. Subjects with symptoms and moderate to severe signs of DED and age matched normal controls were recruited. All subjects were 18 years of age or older and provided written informed consent before undergoing any study-related procedures. Subjects were administered established questionnaires for DED including the Ocular Surface Disease Index and the Standard Patient Evaluation of Eye Dryness to evaluate symptoms. The ocular surface of all subjects was evaluated using a slit lamp biomicroscope to evaluate signs of DED. Sodium fluorescein was instilled in the inferior fornix of each eye using strips wetted with saline; the corneas were assessed for staining in five zones (central, inferior, superior, nasal, and temporal) after one minute using the 0- to 4-point National Eye Institute scale with 0.5-point increments. Conjunctival staining was assessed using lissamine green (LG) strips wetted with saline and applied to the inferior palpebral fornix of each eye. The National Eye Institute scale was also used to grade conjunctival staining which incorporates the van Bijsterveld schema by dividing the nasal and temporal regions each into three zones: superior paralimbal, inferior paralimbal, and peripheral. Each zone is graded on a scale from 0 to 3 for a maximum score of 9 nasally and 9 temporally.<sup>24</sup> The inclusion criteria for symptoms for the DE group were a self-reported history of DE symptoms for 3 months before enrollment, Ocular Surface Disease Index of greater than 10,<sup>25</sup> and Standard Patient Evaluation of Eye Dryness score of 6 or greater<sup>26</sup> at the study visit. For DED signs, ocular surface staining and tear breakup time in the same eye had to be indicative of moderate to severe DED including a corneal fluorescein staining score of 1.5 or higher in at least 1 region in at least 1 eye<sup>27</sup>; total summed corneal fluorescein staining score of 3.0 or

higher<sup>28</sup>; total summed conjunctival LG staining score of 3.0 or higher<sup>28</sup>; and tear breakup time of 10 seconds or less.<sup>29</sup> For the normal controls, Standard Patient Evaluation of Eye Dryness of less than 6, Ocular Surface Disease Index of less than 10, total summed corneal fluorescein staining score of less than 3, total summed conjunctival LG staining score of less than 3, and tear breakup time of more than 10 seconds. Exclusion criteria included current contact lens wear, use of ophthalmic medications within 30 days, pregnant or nursing by self-report, and signs of ocular infection, conjunctival scarring, obvious meibomian gland dysfunction, or other serious ocular condition that may impede study procedures to collect ocular surface samples. A phenol red thread tear test was used to assess tear volume as previously described to evaluate subjects for aqueous deficiency.<sup>30</sup>

### Epithelial Cell Collection

Impression cytology was used to collect ocular surface epithelial cells. This technique involves application of cellulose acetate filter paper to the ocular surface which removes the superficial cell layers of the epithelium. Circular cellulose ester membranes with a 0.45  $\mu\text{m}$  pore size and 13 mm in diameter were acquired (EMD Millipore MF-Millipore; Darmstadt, Germany). The membranes were cut in half to decrease the size for more targeted, regional application of the membrane to the conjunctival surface of the eye. For sample collection on the bulbar conjunctiva, a drop of proparacaine hydrochloride 0.5% was instilled into each eye to temporarily anesthetize the ocular surface. Subjects were asked to look in the opposite direction of the region being sampled; that is, for temporal bulbar collection, the subject was instructed to look nasally. Sterile tweezers were used to hold the semicircle of filter paper, which was applied to the conjunctival surface. The filter paper was held in place for 10 seconds, and then removed and placed into an empty 0.6-mL microcentrifuge tube. This method was repeated for four bulbar conjunctival regions: superior, inferior, nasal, and temporal (Fig. 1). Samples collected from the right and left eyes from the same region were stored together in the same tube per subject. For palpebral conjunctival cell collection, the upper eyelid was everted, and the semicircle of filter paper was applied for 10 seconds to a region that included the lid wiper area. Samples were then immediately placed in a  $-80^{\circ}\text{C}$  freezer until further analysis could be completed.

### Protein Extraction of Epithelial Cells From Impression Cytology Samples

Two semicircle filter papers from both eyes of a single individual were pooled into one protein sample and placed in

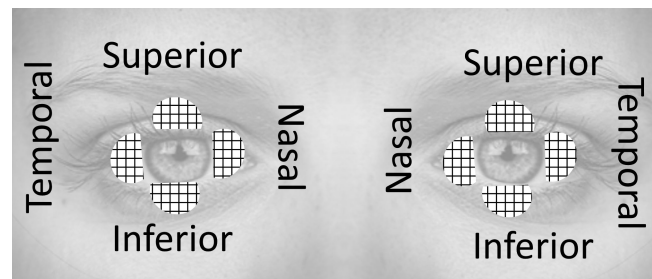


FIGURE 1. Sampling regions. Impression cytology samples were collected from the nasal, temporal, superior, and inferior bulbar conjunctival regions as shown.

200  $\mu$ L of ice-cold 1x RIPA buffer (#9806; Cell Signaling Technology, Danvers, MA, USA) supplemented with 1mM PMSF (#8553; Cell Signaling Technology) immediately before use. During 30 minutes of incubation of the extracts on ice, mechanical homogenization was applied to disrupt the cell membrane using a pestle motor (2 cycles of 30-second bursts with a 15-minute pause each time). Then, samples were centrifuged at 16,000 $\times$ g for 15 minutes at 4°C. The supernatant containing protein extracts was saved into a new tube, concentrated at 40°C for 30 to 50 minutes using a centrifugal vacuum concentrator (Eppendorf, Hamburg, Germany), and tested by JESS capillary-based immunoassay, as described elsewhere in this article. The total protein concentration of the extracts was quantified using Quick Start Bradford 1 $\times$  Dye Reagent (Bio-Rad, Hercules, CA, USA) according to the manufacturer's protocol.

### Simple Western Capillary-Based Immunoassay

JESS, a capillary electrophoresis nano-immunoassay system (Protein Simple, San Jose, CA, USA), was used for the protein expression according to the manufacturer's instruction. Briefly, optimal concentrations of protein and primary antibody were determined through empirical optimization (Supplementary Fig. S1A). An equal amount of protein lysates (0.3  $\mu$ g) was loaded into a 66- to 440-kDa separation module kit (#SM-W008, Protein Simple). Primary antibodies (anti-MUC1 [1:50 dilution; #MAB6298, R&D Systems, Minneapolis, MN, USA], anti-MUC4 [1:50 dilution; #NBP1-52193, Novus, St. Louis, MO, USA], anti-MUC16 [1:50 dilution; #NB120-10032, Novus]), horseradish peroxidase-conjugated secondary antibody (anti-mouse; #DM-002 [Protein Simple] or anti-rabbit; #DM-001 [Protein Simple]) and/or NIR-conjugated mouse secondary antibody (#DM-009, Protein simple) and peroxide/luminol-S (Protein Simple) for chemiluminescent revelation were also loaded on the cartridge. Default assay parameters were used for the separation electrophoresis and immunodetection steps. The calculated chemiluminescence intensity of each single antigen binding signal by the Compass Simple Western software 6.1 (Bio-Techne, San Jose, CA, USA) is presented as an electropherogram format as well as virtual blots. The peak area, chemiluminescence intensity, and the signal/noise ratio of detected proteins were analyzed with the "dropped lines" setting using the integrated Compass software, followed by normalization to the total protein amount (a total protein detection module; #DM-TP01; Protein Simple).

### Statistical Analysis

Statistical analyses and graphical illustrations were conducted using GraphPad Prism 9.1 (GraphPad Software, La Jolla, CA, USA). The data given in figures and text are expressed as mean  $\pm$  SD. A one-way ANOVA or two-way ANOVA followed by multiple comparisons test

(Tukey or Sidak's) were used for data of more than two groups. Spearman correlations were used to evaluate relationships between conjunctival staining grades and mucin protein levels. *P* values of less than 0.05 were considered statistically significant.

## RESULTS

Of the subjects screened, 28 met the inclusion and exclusion criteria for the study, with 16 classified as DED and 12 normal. The demographics for all subjects enrolled including age, sex, ethnicity, and race are listed in Table 1. The DE questionnaire scores and ocular surface characteristics are listed in Table 2. The average phenol red thread test results indicated normal tear volume for both DE ( $22.3 \pm 9.4$  mm) and normal ( $25.8 \pm 7.4$  mm) subjects with no difference between groups (*P* = 0.3). Based on these assessments, subjects in the DE group likely had primarily moderate evaporative DED contributing to significant corneal staining. In some subject samples, there was insufficient sample material to perform mucin analysis for a region of conjunctiva, and so the number of datapoints per region for mucin analysis varies. However, the expression of MUC1, MUC4, and MUC16 was detected in all regions of the bulbar conjunctiva (nasal, temporal, superior, and inferior), as well as in the palpebral conjunctiva of the upper eyelid. See the Supplementary Figures 2 and 3 for full blot images.

### MUC1 Expression

Figures 2A and 2C show representative virtual blots for MUC1 and total protein profile for each region of conjunctiva sampled for normal and DE subjects respectively. In normal

TABLE 1. Demographics

	Normal (n = 12)	DE (n = 16)	P Value
Age (years)			
Mean $\pm$ SD	43.5 $\pm$ 14.6	54.1 $\pm$ 14.1	0.06*
Median	41.0	55.5	
Range (minimum, maximum)	(23, 61)	(26, 81)	
Sex			
Male, n	3	7	0.43†
Female, n	9	9	
Race			
African American	8	6	
Caucasian	2	9	
Asian	2	1	
Ethnicity			
Hispanic	0	1	
Non-Hispanic or non-Latino	12	15	

\* Student *t* test.

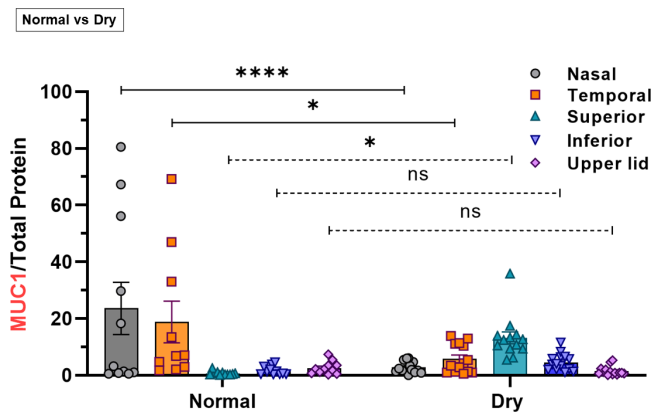
† Fisher's exact test.

TABLE 2. DE Questionnaire Scores and Ocular Surface Characteristics

	Normal (n = 12)	DE (n = 16)	P Value
Ocular Surface Disease Index score	1.0 $\pm$ 1.7	45.1 $\pm$ 24.5	<0.001
Phenol red thread test (mm)	25.8 $\pm$ 7.4	22.3 $\pm$ 9.4	0.3
NaFl tear film breakup time (s)	11.2 $\pm$ 0.9	5.4 $\pm$ 1.7	<0.001
Total corneal staining Lissamine green	0.5 $\pm$ 0.5	5.4 $\pm$ 2.6	<0.001
Conjunctival staining total	0.5 $\pm$ 0.8	8.3 $\pm$ 4.7	<0.001

Data represented as mean  $\pm$  SD, data for right eyes only as applicable, Student's *t* test.





**FIGURE 3.** MUC1 expression in normal vs DE. Significance testing was performed using two-way ANOVA with Sidak's multiple comparison test from  $n = 6-14$ . \*\*\*\* $P < 0.0001$ ; ns, not significant.

conjunctiva sampled in both normal and DE subjects. In normal samples, there were no statistically significant differences across regions of the bulbar conjunctiva nor when compared with the palpebral conjunctiva of the upper eyelid (Fig. 4B). However, in DE samples, MUC4 expression was upregulated in the superior ( $297.6 \pm 32.8$ ) ( $P < 0.0001$ ) and inferior ( $338.5 \pm 27.3$ ) ( $P < 0.0001$ ) bulbar conjunctiva compared with nasal ( $77.3 \pm 7.4$ ), temporal ( $85.6 \pm 5.3$ ), and upper eyelid palpebral ( $100.6 \pm 16.4$ ) conjunctiva (Fig. 3D). When comparing MUC4 expression between normal and DE samples, MUC4 expression was higher in the superior ( $297.6 \pm 32.8$ ) ( $P < 0.0001$ ) and inferior ( $338.5 \pm 27.3$ ) ( $P < 0.0001$ ) bulbar conjunctiva in DE subjects compared with the superior ( $18.5 \pm 4.4$ ) and inferior ( $34.8 \pm 8.3$ ) bulbar conjunctiva in normal subjects, respectively (Fig. 5A).

### MUC16 Expression

Similar to MUC4 expression, there were no significant differences in MUC16 expression across bulbar conjunctival regions nor with the palpebral conjunctiva in the upper eyelid in normal subjects (Fig. 6B). In DE samples, MUC16 expression was higher in the superior ( $11.9 \pm 1.3$ ) ( $P < 0.0001$ ) and inferior ( $10.9 \pm 1.6$ ) ( $P < 0.0001$ ) regions of the bulbar conjunctiva compared with nasal ( $4.4 \pm 0.5$ ), temporal ( $5.1 \pm 0.3$ ), and palpebral ( $1.9 \pm 0.3$ ) conjunctiva of the upper eyelid (Fig. 5D). When comparing MUC16 expression between normal and DE samples, it was observed that MUC16 expression was significantly higher superiorly ( $11.9 \pm 1.3$ ) ( $P < 0.0001$ ) and inferiorly ( $10.9 \pm 1.6$ ) ( $P < 0.0001$ ) in DE samples compared with samples collected from the superior ( $2.1 \pm 0.5$ ) and inferior ( $2.4 \pm 0.4$ ) bulbar regions of normal subjects (Fig. 7A).

### Correlations Between Mucin and Staining

Owing to impression cytology samples being pooled by region from both eyes of each subject, the nasal and temporal conjunctival staining scores were summed for both eyes per subject. The summed nasal and temporal conjunctival staining scores were assessed for associations with MUC1, MUC4, and MUC16 expression in the nasal and temporal regions, respectively. A statistically significant, moderate,

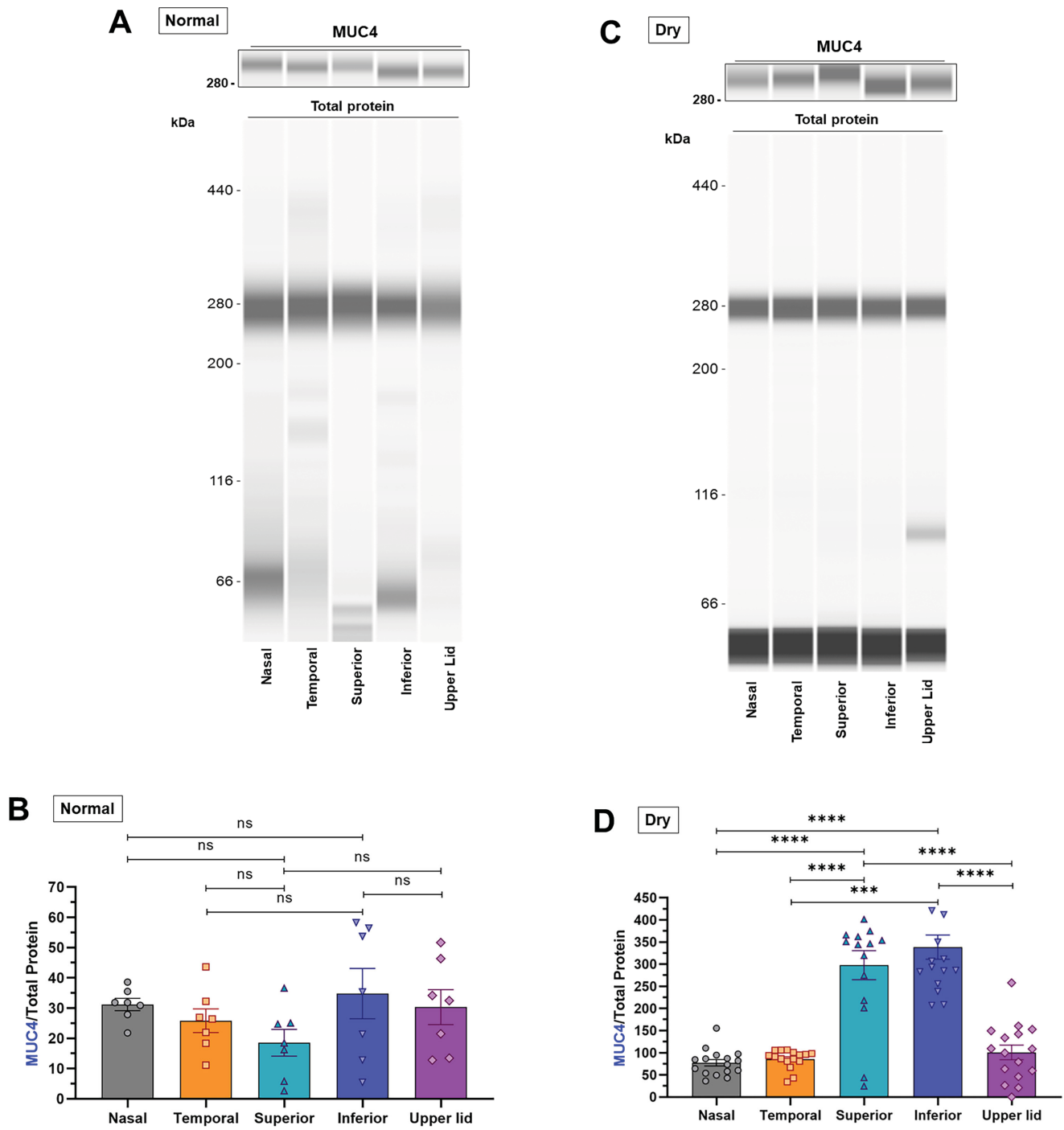
positive correlation was found between MUC4 expression nasally and nasal staining ( $r = 0.68$ ;  $P < 0.001$ ), as well as between MUC4 expression temporally and temporal staining ( $r = 0.49$ ;  $P = 0.02$ ). Figures 8 and 9 show plots for nasal and temporal mucin expression vs. temporal and nasal staining, respectively.

### DISCUSSION

We demonstrate for the first time the expression of MUC1, MUC4, and MUC16 proteins in the palpebral conjunctiva of the upper eyelid. Our investigation extends beyond previous research by examining four distinct regions of the bulbar conjunctiva. The purpose was to determine whether MAMs are expressed at similar levels across these regions in individuals with a healthy ocular surface, and to compare these levels with those observed in individuals with DE conditions. Until now, studies investigating MAMs on the ocular surface have been limited primarily to the bulbar conjunctiva, cornea, and tear film to unravel the various functions of these mucins in the eye.<sup>31-33</sup>

MAMs play a crucial role in adhering to and anchoring the hydrophobic epithelial surface of the eye. The high glycosylation of these mucins imparts a negative charge and owing to steric constraints, creates a brush-like hydrophilic covering known as the glycocalyx that helps the tear film to adhere to and lubricate the surface of the eye.<sup>34</sup> This brush-like glycocalyx covering also helps to decrease the coefficient of friction on the surface of the eye during eyelid blinking, ensuring smoother movement.<sup>34</sup> The presence of MUC1, MUC4, and MUC16 proteins in the lid wiper of the upper eyelid's palpebral conjunctiva could indicate a role in minimizing friction between the cornea and conjunctiva and the eyelid during blinking.<sup>35</sup> The lubrication system on the ocular surface is mainly a hydrodynamic lubrication regime, whereby the eye's surface and eyelid are fully separated by the fluid of the tear film.<sup>5,35</sup> In this type of regime, friction primarily depends on the properties of the tear film, namely, viscosity, which is governed by mucins and other proteins in the tear fluid.<sup>35</sup> However, in conditions such as DED, where the tear fluid is decreased, contact between the eye's surface and the eyelid may occur, resulting in a boundary lubrication regime.<sup>35</sup> In this type of regime, the quality of the surface of the eyelid would become crucial in determining friction. If MAMs in the eyelid become damaged or absent, the resultant increased friction, albeit possibly minor, may contribute to the observed ocular surface damage in severe DED.

Statistically significant differences in expression of MUC1, but not MUC4 or MUC16, were found across regions of the bulbar conjunctiva in normal subjects. MUC1 was expressed significantly higher nasally when compared with the superior and inferior bulbar conjunctival regions. The individual function of MUC1 on the ocular surface has not been elucidated. However, MUC1 is expressed in normal oral, respiratory, digestive, and other mucosal epithelia of the body, where it lubricates and protects the tracts, airways, and organ linings and may provide some barrier to pathogen adherence.<sup>36-38</sup> Additionally, MUC1 is overexpressed on cancer cells where studies in vitro demonstrate that it plays a role in metastasis and tumor invasion as an antiadhesive glycoprotein.<sup>39,40</sup> Based on the findings of this study, it is plausible to suggest that MUC1 may play a protective and antiadhesive role specifically in the nasal region of the



**FIGURE 4.** MUC4 expression. (A) JESS capillary-based Western for MUC4 in protein lysates from impression cytology of nasal, temporal, superior, inferior conjunctiva and upper eyelid of normal eye subjects. Representative virtual blots for MUC4 and total protein profile are shown (B) Quantification of JESS capillary-based Western from (A). Significance testing was performed using one-way ANOVA with Tukey's multiple comparison test from n = 7. ns, not significant. (C) JESS capillary-based Western for MUC4 in protein lysates from impression cytology of nasal, temporal, superior, inferior conjunctiva and upper eyelid of DE subjects. (D) Quantification of JESS capillary-based Western from (C). Significance testing was performed using one-way ANOVA with Tukey's multiple comparison test from n = 16. \*\*\**P* < 0.0002; \*\*\*\**P* < 0.0001; ns, not significant.

bulbar conjunctiva, although additional studies are needed to confirm these results.

In DE subjects, significant upregulation of MUC1 was observed in superior region, whereas MUC4 and MUC16

were upregulated in both superior and inferior regions of the conjunctiva. The O-glycans attached to MAMs facilitate disadhesion between cells of the palpebral conjunctiva, cornea, and bulbar conjunctiva.<sup>41,42</sup> Altered glycosyla-

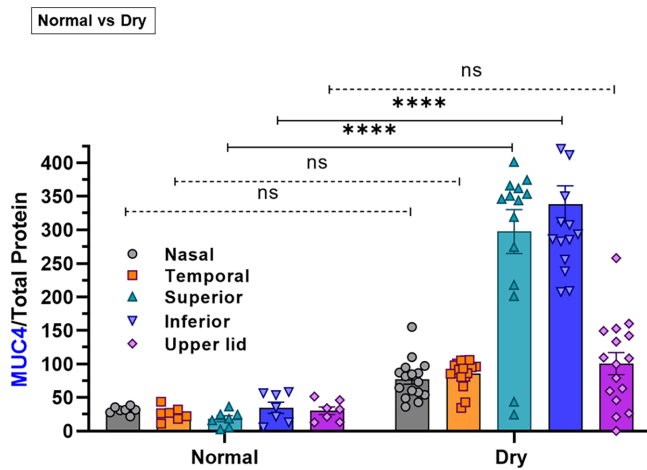


FIGURE 5. MUC4 expression in normal vs DE. Significance testing was performed using two-way ANOVA with Sidak's multiple comparison test from  $n = 7-16$ . \*\*\*\* $P < 0.0001$ ; ns, not significant.

tion and disruption of the O-glycan attachments to MAMs, which may occur in DED, could lead to increased adhesion between the eyelid and ocular surface, resulting in damage to the epithelial surface.<sup>43</sup> Upregulation of MAMs in the superior and inferior bulbar conjunctiva in DE, the primary regions within the pathway of eyelid blinking, may serve as a protective mechanism in an attempt to promote disadhesion between the eyelid and the ocular surface. If the adhesive force between the palpebral conjunctiva and ocular surface epithelium is too great, the high shearing force can peel the corneal epithelium from the underlying basement membrane, resulting in a painful corneal erosion, a condition that occurs at a greater frequency in those with DED.<sup>44</sup>

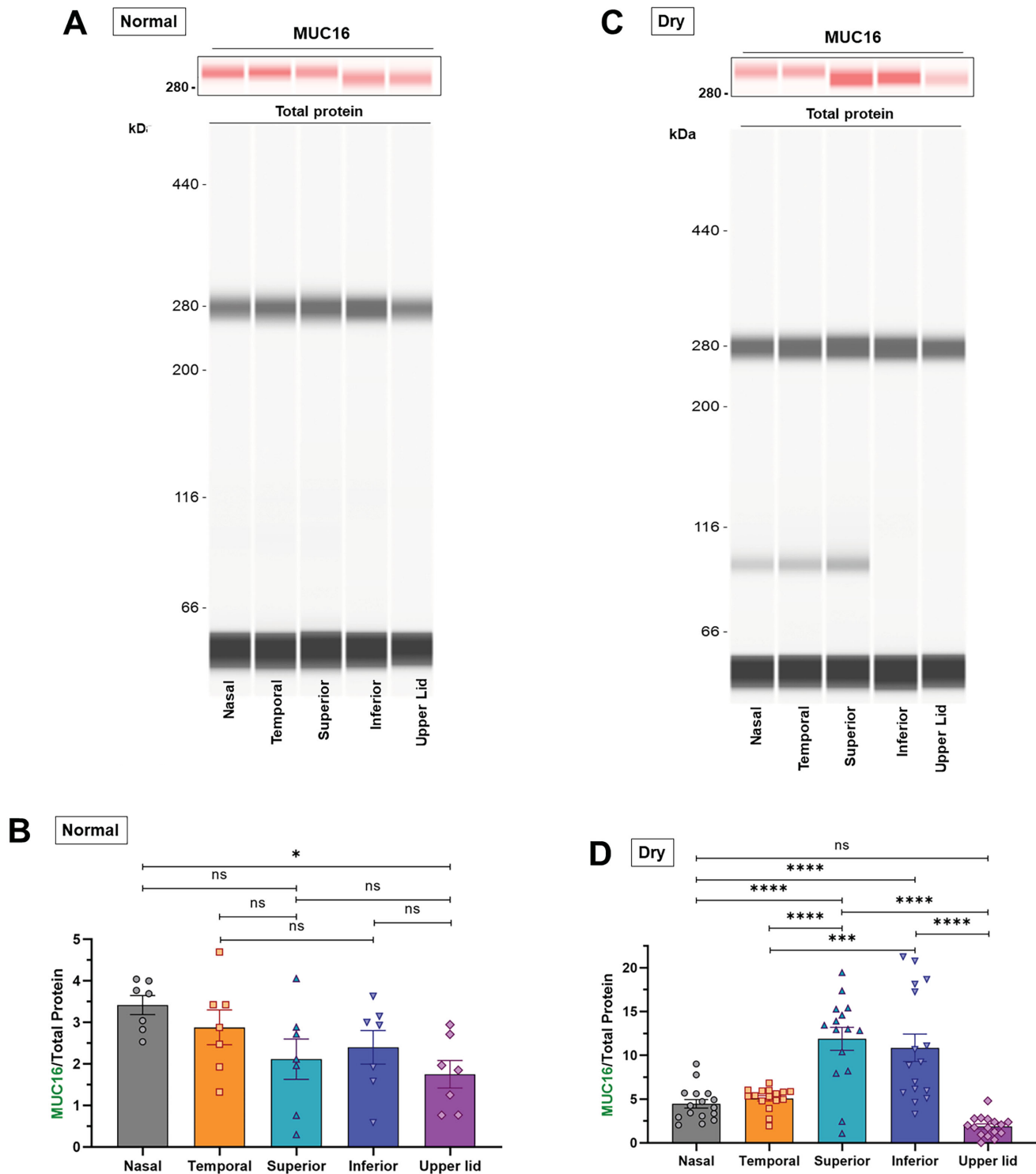
Significant differences were observed in the expression of each MAM regionally between normal and DE subjects. In DE subjects, MUC1 was upregulated in the superior conjunctiva but downregulated nasally and temporally when compared with normal subjects. Both MUC4 and MUC16 were significantly upregulated superiorly and inferiorly in DE subjects compared with normal subjects. DED has core mechanisms of tear film instability and inflammation, which results in ocular surface damage if left untreated.<sup>45</sup> MAMs contribute to lubrication of the ocular surface by stabilizing the tear film.<sup>46</sup> Therefore, alterations in MAMs in DED could potentially disrupt the tear film. Several investigators have reported varying findings concerning the expression of MAMs in DED. Although some investigators report increases,<sup>17,19,47</sup> others indicate decreases<sup>18,48</sup> or no changes in expression.<sup>16,20</sup> To clarify, and reach a more definitive understanding, further studies are required to resolve these discrepancies. However, as the results presented in this article show, conjunctival regions from which MAM samples are collected can impact resulting conclusions. Regional differences in MAM expression exist in normal individuals, such as MUC1 expression being higher nasally, and the expression of each MAM can be affected differently in DED depending on the region, such as MUC4 and MUC16 expression being higher superiorly and inferiorly vs. MUC1 expression only higher superiorly, which may explain some of the discrepancies noted by other investigators. Therefore, it is crucial for future investigators to consider these regional

differences when selecting sampling regions for MAM evaluation.

Another explanation for these discrepancies is subject selection for DED. Historically, patients with DED have been classified as primarily evaporative, where the tear film evaporates too quickly, or aqueous deficient, where there is a low volume of tears being produced. It is now thought that the majority of individuals with DED have a combination of both types with the evaporative mechanism present in approximately 80% of DED patients.<sup>49</sup> Studies analyzing mucin differences in DED must report inclusion and exclusion criteria to understand the type of DED under analysis. In the current study, DED subjects had normal tear volumes and primarily evaporative DE with significant keratitis.

Secondary analyses looked at whether MAM expression in nasal and temporal bulbar conjunctival regions was correlated with LG staining in the same area. Moderate, statistically significant correlations were found between MUC4 expression and staining temporally along with MUC4 expression and staining nasally. Nonsignificant correlations were seen between MUC1 and MUC16 expression and staining. Clinical dyes such as LG, sodium fluorescein, and Rose Bengal are used clinically to assess damage to epithelial cells in DED.<sup>50,51</sup> Although the mechanisms of staining are debated, hyper-fluorescent punctate staining seen on the ocular surface in DED are likely caused by barrier dysfunction such as loss of mucin, apoptosis of cells, or abnormal pooling in areas lacking epithelial cells.<sup>52,53</sup> Past in vitro studies have shown the exclusion of Rose Bengal on corneal and conjunctival epithelial cells in culture that express MUC16.<sup>54,55</sup> Because Rose Bengal is not commonly used clinically owing to increased patient discomfort compared with LG,<sup>56</sup> our aim here was to evaluate any potential correlation with increased LG staining with mucin expression. Because MUC4 expression was found to be correlated with LG staining, it is possible that clinicians can interpret LG staining as an indicator of alteration in MUC4 expression, although more studies are needed to confirm this finding.

Analyzing ocular surface mucins often encounters the limitation of a small sample size and volume. Despite the noninvasive nature of the collection process using impression cytology from the bulbar conjunctiva, it remains an uncomfortable experience for the majority of patients, even with the application of topical anesthesia. To yield higher quantities of mucin, our study implemented a comprehensive sampling approach, encompassing both eyes and all regions of the conjunctiva, resulting in the collection of 10 samples from each subject. Despite this diligent sampling strategy, numerous samples still presented suboptimal quantities for analysis. The challenges associated with mucin analysis arise from their high glycosylation and high molecular weight, making detection and analysis in human samples problematic owing to issues, such as unspecific antibody binding and the requirement for low limits of detection, which are especially critical for small sample quantities. However, our study has successfully demonstrated the specific detection of each mucin protein using dedicated antibodies, even within the constraints of a limited sample size (average of  $<4 \mu\text{g}/\mu\text{L}$  per eye). Moving forward, we aim to enhance the robustness of our findings by increasing the sample size and exploring additional research questions in upcoming studies.



**FIGURE 6.** MUC16 expression. **(A)** JESS capillary-based Western for MUC16 in protein lysates from impression cytology of nasal, temporal, superior, inferior conjunctiva and upper eyelid of normal eye subjects. Representative virtual blots for MUC16 detected with mouse NIR fluorescence secondary antibody and total protein profile are shown. **(B)** Quantification of JESS capillary-based Western from **(A)**. Significance testing was performed using one-way ANOVA with Tukey's multiple comparison test from  $n = 7$ .  $P < 0.0032$ ; ns, not significant. **(C)** JESS capillary-based Western for MUC16 in protein lysates from impression cytology of nasal, temporal, superior, inferior conjunctiva and upper eyelid of DE subjects. **(D)** Quantification of JESS capillary-based Western from **(C)**. Significance testing was performed using one-way ANOVA with Tukey's multiple comparison test from  $n = 16$ . \*\*\* $P < 0.0002$ ; \*\*\*\* $P < 0.0001$ ; ns, not significant.

In conclusion, MUC1, MUC4, and MUC16 expression was detected in the upper eyelid palpebral conjunctiva, suggest-

ing a role for MAMs in the lid wiper region. Although the overall function of MUC1, MUC4, and MUC16 is to form the



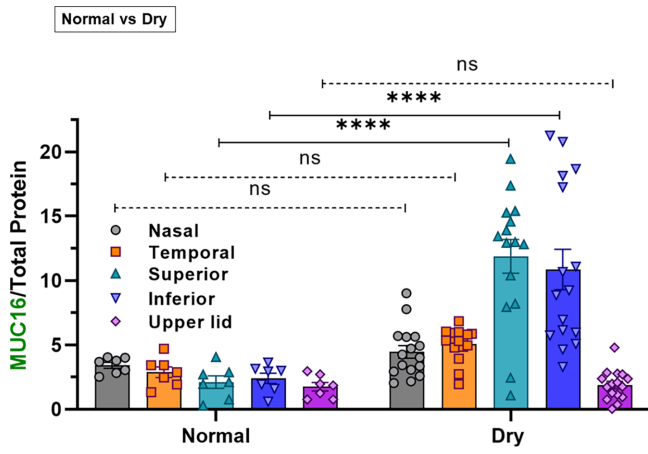


FIGURE 7. MUC16 expression in normal vs DE. Significance testing was performed using two-way ANOVA with Sidak's multiple comparison test from  $n = 7-16$ . \*\*\*\* $P < 0.0001$ ; ns, not significant.

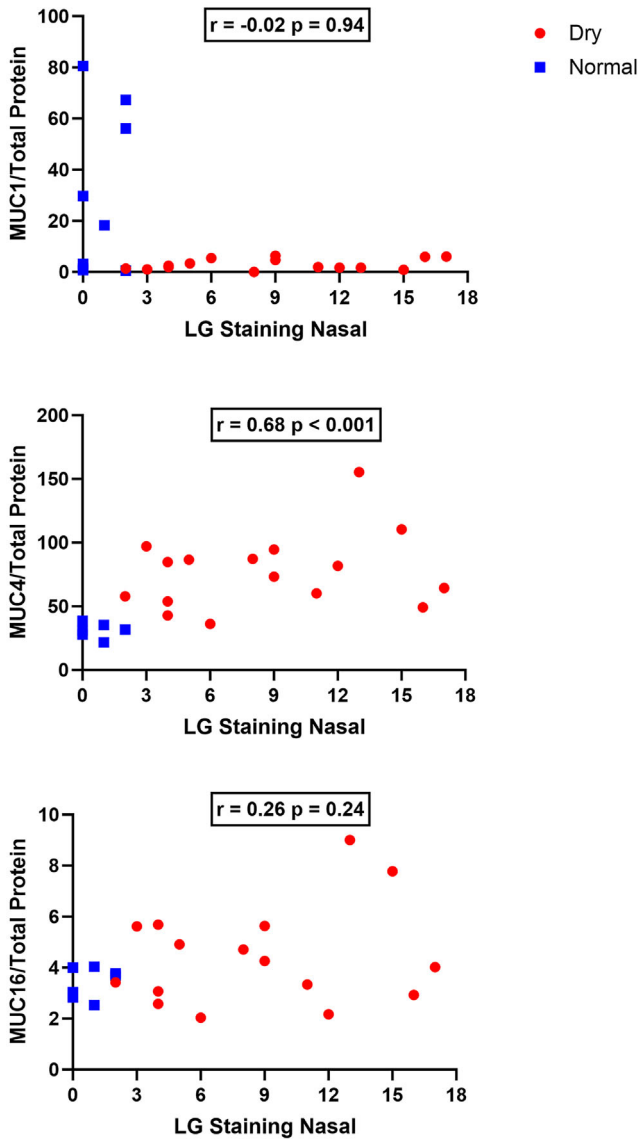


FIGURE 8. Mucin expression and nasal LG staining. Correlation of MUC1, MUC4, and MUC16 expression with LG staining in the nasal bulbar conjunctiva.

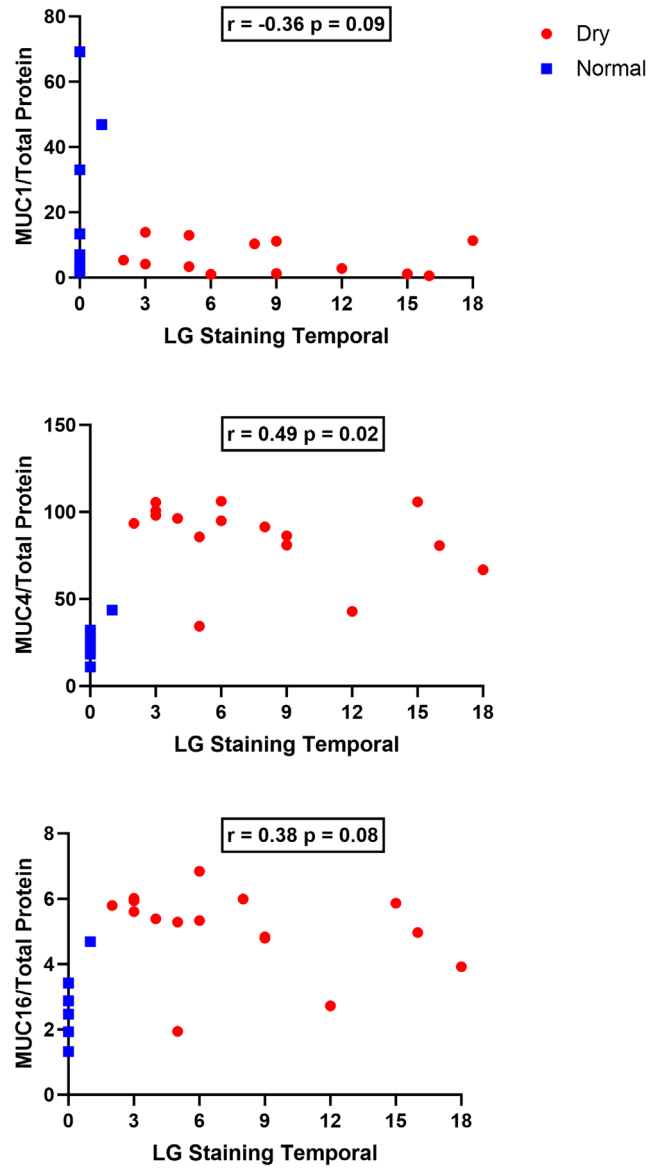


FIGURE 9. Mucin expression and temporal LG staining. Correlation of MUC1, MUC4, and MUC16 expression with LG staining in the temporal bulbar conjunctiva.

glycocalyx, each mucin may have additional unique functions that are currently unexplored. The elevated expression of MUC1 in the nasal bulbar conjunctiva of healthy subjects suggests a functional need for increased lubrication and protection against pathogen adhesion in this area. Regional differences in expression on the bulbar conjunctiva in normal subjects were not seen for MUC4 or MUC16. When comparing DE with normal samples, there was an upregulation of MUC1 superiorly, and in both MUC4 and MUC16 both superiorly and inferiorly, which may indicate a need to decrease friction between the eyelid and ocular surface in patients with DE during blinking. LG staining may be an indicator of alterations in mucin expression in the conjunctiva. MUC16 has a multifunctional role as a component of the glycocalyx, and its unique and critical functions may warrant ubiquitous expression across all regions of the bulbar conjunctiva.

## Acknowledgments

The authors thank Catherine Cheng for helpful suggestions on JESS experiments and use of the JESS instrument.

Supported by the National Institutes of Health grant K23EY027845.

Disclosure: **M. Choi**, None; **A.A. Tichenor**, None

## References

- Govindarajan B, Gipson IK. Membrane-tethered mucins have multiple functions on the ocular surface. *Exp Eye Res.* 2010;90(6):655–663.
- Hatstrup CL, Gendler SJ. Structure and function of the cell surface (tethered) mucins. *Annu Rev Physiol.* 2008;70:431–457.
- Inatomi T, Spurr-Michaud S, Tisdale AS, Zhan Q, Feldman ST, Gipson IK. Expression of secretory mucin genes by human conjunctival epithelia. *Invest Ophthalmol Vis Sci.* 1996;37(8):1684–1692.
- Gipson IK. Goblet cells of the conjunctiva: a review of recent findings. *Prog Retin Eye Res.* 2016;54:49–63.
- Knop N, Korb DR, Blackie CA, Knop E. The lid wiper contains goblet cells and goblet cell crypts for ocular surface lubrication during the blink. *Cornea.* 2012;31(6):668–679.
- Argueso P, Spurr-Michaud S, Russo CL, Tisdale A, Gipson IK. MUC16 mucin is expressed by the human ocular surface epithelia and carries the H185 carbohydrate epitope. *Invest Ophthalmol Vis Sci.* 2003;44(6):2487–2495.
- Gipson IK. Distribution of mucins at the ocular surface. *Exp Eye Res.* 2004;78(3):379–388.
- Pflugfelder SC, Liu Z, Monroy D, et al. Detection of sialomucin complex (MUC4) in human ocular surface epithelium and tear fluid. *Invest Ophthalmol Vis Sci.* 2000;41(6):1316–1326.
- Sheehan JK, Kesimer M, Pickles R. Innate immunity and mucus structure and function. *Novartis Found Symp.* 2006;279:155–166; discussion 67–69, 21621–9.
- Gipson IK, Spurr-Michaud S, Tisdale A, Menon BB. Comparison of the transmembrane mucins MUC1 and MUC16 in epithelial barrier function. *PLoS One.* 2014;9(6):e100393.
- Guang W, Ding H, Czinn SJ, Kim KC, Blanchard TG, Lillehoj EP. Muc1 cell surface mucin attenuates epithelial inflammation in response to a common mucosal pathogen. *J Biol Chem.* 2010;285(27):20547–20557.
- Dhar P, McAuley J. The role of the cell surface mucin MUC1 as a barrier to infection and regulator of inflammation. *Front Cell Infect Microbiol.* 2019;9:117.
- Ralph RA. Conjunctival goblet cell density in normal subjects and in DE syndromes. *Invest Ophthalmol.* 1975;14(4):299–302.
- Khimani KS, Go JA, De Souza RG, et al. Regional comparison of goblet cell number and area in exposed and covered dry eyes and their correlation with tear MUC5AC. *Sci Rep.* 2020;10(1):2933.
- Zhao H, Jumblatt JE, Wood TO, Jumblatt MM. Quantification of MUC5AC protein in human tears. *Cornea.* 2001;20(8):873–877.
- Berry M. Human preocular mucins reflect changes in surface physiology. *Br J Ophthalmol.* 2004;88(3):377–383.
- Paulsen F, Langer G, Hoffmann W, Berry M. Human lacrimal gland mucins. *Cell Tissue Res.* 2004;316(2):167–177.
- Corrales RM, Narayanan S, Fernandez I, et al. Ocular mucin gene expression levels as biomarkers for the diagnosis of dry eye syndrome. *Invest Ophthalmol Vis Sci.* 2011;52(11):8363–8369.
- Gipson IK, Spurr-Michaud SJ, Senchyna M, Ritter R, 3rd, Schaumberg D. Comparison of mucin levels at the ocular surface of postmenopausal women with and without a history of dry eye. *Cornea.* 2011;30(12):1346–1352.
- Srinivasan S, Heynen ML, Martell E, Ritter R, 3rd, Jones L, Senchyna M. Quantification of MUCIN 1, cell surface associated and MUCIN16, cell surface associated proteins in tears and conjunctival epithelial cells collected from postmenopausal women. *Mol Vis.* 2013;19:970–979.
- Shimazaki-Den S, Dogru M, Higa K, Shimazaki J. Symptoms, visual function, and mucin expression of eyes with tear film instability. *Cornea.* 2013;32(9):1211–1218.
- Kessing SV. Mucous gland system of the conjunctiva. A quantitative normal anatomical study. *Acta Ophthalmol (Copenb).* 1968;Suppl 95:1+.
- Egbert PR, Lauber S, Maurice DM. A simple conjunctival biopsy. *Am J Ophthalmol.* 1977;84(6):798–801.
- van Bijsterveld OP. Diagnostic tests in the Sicca syndrome. *Arch Ophthalmol.* 1969;82(1):10–14.
- Schiffman RM, Christianson MD, Jacobsen G, Hirsch JD, Reis BL. Reliability and validity of the Ocular Surface Disease Index. *Arch Ophthalmol.* 2000;118(5):615–621.
- Ngo W, Situ P, Keir N, Korb D, Blackie C, Simpson T. Psychometric properties and validation of the Standard Patient Evaluation of Eye Dryness questionnaire. *Cornea.* 2013;32(9):1204–1210.
- Bron A. Methodologies to diagnose and monitor dry eye disease: report of the Diagnostic Methodology Subcommittee of the International Dry Eye WorkShop (2007). *The Ocular Surface.* 2007;5(2):108–152.
- Lemp MA. Report of the National Eye Institute/Industry workshop on Clinical Trials in Dry Eyes. *CLAO J.* 1995; 21(4):221–232.
- Lemp MA, Baudouin C, Baum J, Dogru M. The definition and classification of dry eye disease: report of the Definition and Classification Subcommittee of the International Dry Eye WorkShop (2007). *The Ocular Surface.* 2007;5(2):75–92.
- Patel S, Farrell J, Blades KJ, Grierson DJ. The value of a phenol red impregnated thread for differentiating between the aqueous and non-aqueous deficient dry eye. *Ophthalmic Physiol Opt.* 1998;18(6):471–476.
- Argueso P, Gipson IK. Epithelial mucins of the ocular surface: structure, biosynthesis and function. *Exp Eye Res.* 2001;73(3):281–289.
- Blalock TD, Spurr-Michaud SJ, Tisdale AS, et al. Functions of MUC16 in corneal epithelial cells. *Invest Ophthalmol Vis Sci.* 2007;48(10):4509–4518.
- Spurr-Michaud S, Argueso P, Gipson I. Assay of mucins in human tear fluid. *Exp Eye Res.* 2007;84(5):939–950.
- Coles JM, Chang DP, Zauscher S. Molecular mechanisms of aqueous boundary lubrication by mucinous glycoproteins. *Curr Opin Colloid Interface Sci.* 2010;15(6):406–416.
- Pult H, Tosatti SG, Spencer ND, Asfour JM, Ebenhoch M, Murphy PJ. Spontaneous blinking from a tribological viewpoint. *Ocul Surf.* 2015;13(3):236–249.
- Lu W, Hisatsune A, Koga T, et al. Cutting edge: enhanced pulmonary clearance of *Pseudomonas aeruginosa* by Muc1 knockout mice. *J Immunol.* 2006;176(7):3890–3894.
- Ma J, Rubin BK, Voynow JA. Mucins, Mucus, and Goblet Cells. *Chest.* 2018;154(1):169–176.
- McGuckin MA, Every AL, Skene CD, et al. Muc1 mucin limits both *Helicobacter pylori* colonization of the murine gastric mucosa and associated gastritis. *Gastroenterology.* 2007;133(4):1210–1218.
- Hilkens J, Ligtenberg MJ, Vos HL, Litvinov SV. Cell membrane-associated mucins and their adhesion-modulating property. *Trends Biochem Sci.* 1992;17(9):359–363.

40. Hilkens J, Vos HL, Wesseling J, et al. Is episialin/MUC1 involved in breast cancer progression? *Cancer Lett.* 1995; 90(1):27–33.
41. Argueso P. Glycobiology of the ocular surface: mucins and lectins. *Jpn J Ophthalmol.* 2013;57(2):150–155.
42. Komatsu M, Carraway CA, Fregien NL, Carraway KL. Reversible disruption of cell-matrix and cell-cell interactions by overexpression of sialomucin complex. *J Biol Chem.* 1997;272(52):33245–33254.
43. Ciborowski P, Finn OJ. Non-glycosylated tandem repeats of MUC1 facilitate attachment of breast tumor cells to normal human lung tissue and immobilized extracellular matrix proteins (ECM) in vitro: potential role in metastasis. *Clin Exp Metastasis.* 2002;19(4):339–345.
44. Miller DD, Hasan SA, Simmons NL, Stewart MW. Recurrent corneal erosion: a comprehensive review. *Clin Ophthalmol.* 2019;13:325–335.
45. Craig JP, Nichols KK, Akpek EK, et al. TFOS DEWS II definition and classification report. *Ocul Surf.* 2017;15(3):276–283.
46. Ablamowicz AF, Nichols JJ. Ocular surface membrane-associated mucins. *Ocul Surf.* 2016;14(3):331–341.
47. Hayashi Y, Kao WW, Kohno N, et al. Expression patterns of sialylated epitope recognized by KL-6 monoclonal antibody in ocular surface epithelium of normals and dry eye patients. *Invest Ophthalmol Vis Sci.* 2004;45(7):2212–2217.
48. Danjo Y, Watanabe H, Tisdale AS, et al. Alteration of mucin in human conjunctival epithelia in dry eye. *Invest Ophthalmol Vis Sci.* 1998;39(13):2602–2609.
49. Lemp MA, Crews LA, Bron AJ, Foulks GN, Sullivan BD. Distribution of aqueous-deficient and evaporative dry eye in a clinic-based patient cohort: a retrospective study. *Cornea.* 2012;31(5):472–478.
50. Korb DR, Herman JP, Finnemore VM, Exford JM, Blackie CA. An evaluation of the efficacy of fluorescein, rose Bengal, lissamine green, and a new dye mixture for ocular surface staining. *Eye Contact Lens.* 2008;34(1):61–64.
51. Norn MS. Vital staining of cornea and conjunctiva. Fluorescein-rose Bengal mixture and tetrazolium-alcian blue mixture. *Acta Ophthalmol Suppl.* 1972;113:3–66.
52. Bron AJ, Argueso P, Irkec M, Bright FV. Clinical staining of the ocular surface: mechanisms and interpretations. *Prog Retin Eye Res.* 2015;44c:36–61.
53. Bandamwar KL, Papas EB, Garrett Q. Fluorescein staining and physiological state of corneal epithelial cells. *Contact Lens Anterior Eye.* 2014;37(3):213–223.
54. Argueso P, Sumiyoshi M. Characterization of a carbohydrate epitope defined by the monoclonal antibody H185: sialic acid O-acetylation on epithelial cell-surface mucins. *Glycobiology.* 2006;16(12):1219–1228.
55. Argueso P, Guzman-Aranguez A, Mantelli F, Cao Z, Ricciuto J, Panjwani N. Association of cell surface mucins with galectin-3 contributes to the ocular surface epithelial barrier. *J Biol Chem.* 2009;284(34):23037–23045.
56. Machado LM, Castro RS, Fontes BM. Staining patterns in dry eye syndrome: rose bengal versus lissamine green. *Cornea.* 2009;28(7):732–734.