

Short-Term Myopic Defocus and Choroidal Thickness in Children and Adults

Lisa A. Ostrin, Raman P. Sah, Hope M. Queener, Nimesh B. Patel, Raphaella Tran, Divya Shukla, and Hanieh Mirhajianmoghadam

University of Houston College of Optometry, Houston, TX, United States

Correspondence: Lisa A. Ostrin, University of Houston College of Optometry, 4401 MLK Blvd., Houston, TX 77204, USA; lostrin@central.uh.edu.

Received: September 11, 2023

Accepted: March 20, 2024

Published: April 10, 2024

Citation: Ostrin LA, Sah RP, Queener HM, et al. Short-term myopic defocus and choroidal thickness in children and adults. *Invest Ophthalmol Vis Sci.* 2024;65(4):22. <https://doi.org/10.1167/iovs.65.4.22>

PURPOSE. Studies report conflicting findings regarding choroidal thickness changes in response to myopic defocus in humans. This study aimed to investigate the choroidal response to myopic defocus in children and adults using automated analysis.

METHODS. Participants (N = 46) were distance-corrected in both eyes and viewed a movie on a screen for 10 minutes. Two optical coherence tomography (OCT) radial scans were collected for each eye, then +3 diopters was added to one eye. Participants continued to watch the movie, OCT scans were repeated every 10 minutes for 50 minutes, and then recovery was assessed at 60 and 70 minutes. Defocus was interrupted for approximately two out of each 10 minutes for OCT imaging. OCT images were analyzed using an automated algorithm and trained neural network implemented in MATLAB to determine choroidal thickness at each time point. Repeated-measures ANOVA was used to assess changes with time in three age groups (6–17, 18–30, and 31–45 years) and by refractive error group (myopic and nonmyopic).

RESULTS. Choroidal thickness was significantly associated with spherical equivalent refraction, with the myopic group having a thinner choroid than the nonmyopic group ($P < 0.001$). With imposed myopic defocus, there were no significant changes in choroidal thickness at any time point for any age group and for either refractive error group ($P > 0.05$ for all).

CONCLUSIONS. Findings demonstrate that, using the described protocol, the choroidal thickness of children and adults does not significantly change in response to short-term, full-field myopic defocus, in contrast to several previously published studies.

Keywords: choroid, defocus, myopia

The prevalence of myopia has been increasing in children and adults, with estimates predicting that 50% of the world population will be myopic by 2050 and 9.8% of the population will be highly myopic.¹ There is significant interest in developing strategies for myopia control to slow progression and reduce associated pathology because any degree of myopia carries increased risk of retinal degeneration,² glaucoma,³ cataract,⁴ and retinal detachment.⁵ Myopia represents a significant socioeconomic burden because of loss of productivity.⁶ By reducing the prevalence and progression of myopia, significant reductions in the socioeconomic burden and improvements in quality of life can be achieved. Optical treatments to slow myopia progression include bifocal and progressive addition spectacles, orthokeratology contact lenses, and soft multifocal lenses.^{7,8} New spectacle lens designs have recently been introduced that incorporate integrated lenslets of aspheric or plus power in the midperiphery of the lens.^{9,10} These treatments induce myopic defocus in the midperipheral and peripheral retina and result in slowed axial elongation. Although the mechanism of action has not been fully clarified, myopic peripheral defocus, when presented simultaneously with an in-focus image plane, is hypothesized to provide a stop signal for

eye growth. The choroid may be a potential mediator in this pathway. However, there have been conflicting results regarding choroid effects in children undergoing myopia control. For example, after orthokeratology, one study found no significant changes in choroid thickness¹¹ and another study reported choroidal thickening.¹² Additionally, a recent study showed there were no significant changes in choroidal thickness in adults wearing multifocal center distance or center near lenses for 30 minutes.¹³

The choroid may play a significant role in myopia development and in myopia control. In young animals undergoing experimental myopia, including chicks,^{14,15} guinea pigs,¹⁶ tree shrews,¹⁷ and marmoset¹⁸ and rhesus monkeys,¹⁹ defocus-induced choroidal changes precede longer term changes in ocular growth.^{14,19} As the choroidal thickness changes, the photoreceptors are brought closer to the image plane. For example, hyperopic defocus induced by full-field minus powered lenses results in choroidal thinning and ultimately, longer-term increases in axial growth.^{14,19} The rapid, bidirectional response of the choroid may be one of the first steps in the signaling cascade that ultimately leads to alterations in scleral remodeling and growth rate. Similarly, in young adults, the choroid has been shown to



respond within two minutes of imposed defocus, and upon removal of the defocus, the choroid returns to baseline.²⁰ Of note, experiments in animal models are performed during the rapid emmetropization phase, when the eye can most robustly adjust growth to compensate for defocus. On the other hand, investigations of choroidal thickness changes in humans take place after the rapid emmetropization phase (i.e., greater than three years of age). It is possible that the choroid is under different control in these two circumstances. Indeed, the role of the choroid in human myopia has yet to be elucidated. It has been hypothesized that thinning of the choroid leads to scleral hypoxia, which may contribute to myopia development.²¹

The mechanism of choroidal modulation in response to defocus is not well understood. The choroid is a dynamic vascular structure that supplies nutrients and oxygen to the outer retina and sclera. Changes in choroidal thickness due to defocus have been suggested to be mediated by changes in blood flow,²² altered tonus of the nonvascular smooth muscle of the choroid,²³ and, particularly in chicks, changes in size of lacunae.^{23,24} However, in humans, transient defocus-induced choroidal thickness changes reported in previous studies are small, on the order of 5 to 20 μm ,^{25,26} and therefore difficult to precisely quantify given the resolution of modern instrumentation. Furthermore, several studies have reported that no significant changes in the choroid were observed with myopic defocus^{13,26,27} or that choroidal thickening only occurs in emmetropic but not myopic eyes.²⁸

Most commonly, choroidal thickness is quantified from optical coherence tomography (OCT) imaging using manual segmentation of the choroid/sclera border.²⁹ Choroidal thickness changes can also be indirectly observed from axial length changes. For example, instruments using optical coherence biometry, such as the LenStar biometer (Haag-Streit AG, Koeniz, Switzerland), measure axial length from the cornea to the retinal pigment epithelium. Therefore it may be inferred that a transient decrease in axial length corresponds to an increase in choroidal thickness, and vice versa. Contributing to challenges in accurately quantifying short-term changes in choroidal thickness include the many other physiological and environmental factors that have been shown to influence the choroid, such as diurnal variation^{30,31} and light exposure.³² Diurnal changes in choroidal thickness are characterized by thinning until midday and thickening throughout the night, in an antiphase relationship with axial length diurnal variation.³¹ Light exposure may confound choroidal thickness measurements, as studies suggest that the choroid is sensitive to ambient illumination and spectral composition of light.^{33–35}

This study aimed to assess the response of the choroid to myopic defocus using controlled experimental conditions and objective image analysis techniques. Age and refractive error group effects were assessed. These findings may help better understand the role of the choroid in response to optical-based myopia treatments in children.

METHODS

Participants

Participants between the ages of 6 to 45 years were recruited and were classified as children (ages 6 to <18 years), young adults (18 to 30 years), or older adults (>30 to 45 years). Participants were screened to ensure good ocular health. All participants had best-corrected monocular visual acuity of

20/25 or better with habitual correction. Exclusion criteria were a history of ocular disease or trauma. The study was approved by the institutional review board at the University of Houston and procedures followed the tenets of the Declaration of Helsinki. All participants provided informed consent or parental permission and children's assent after the nature of the study was explained.

Protocol

Each session began between 8:00 AM and 9:30 AM to minimize effects of diurnal variations in choroidal thickness. Participants were asked to refrain from caffeine and vigorous exercise prior to the experiment because previous studies suggest these variables may affect choroidal thickness.²⁹ The experimental protocol is shown in [Figure 1](#). Participants first underwent biometry and autorefractive measurements. Axial length was measured in both eyes using a noncontact low-coherence optical biometer (LenStar, Haag-Streit, K niz, Switzerland). Five measurements were collected and averaged for each eye. Then, noncycloplegic refractive error was measured in both eyes using an open-field autorefractor (WAM-5000; Grand Seiko, Hiroshima, Japan). Five measurements were collected, and the average was used to determine spherical equivalent refractive error (SER) for each eye. Participants were classified as nonmyopic (SER > -0.50 diopters [D]) or myopic (SER \leq -0.50 D) based on the SER of the right eye.

For baseline and recovery, participants wore a trial frame that held their distance correction plus an additional +0.5 D; the +0.5 D accounted for the 2 m viewing distance of the projector screen. The screen was 2.1 m wide \times 1.2 m tall and subtended a horizontal and vertical field of view of 56 $^\circ$ \times 34 $^\circ$, respectively. The luminance of the screen was approximately 150 cd/m² (Luminance Meter LS-110; Konica Minolta, Tokyo, Japan). Before the first measurement, participants underwent a distance viewing period of 10 minutes to standardize the conditions under which the choroid was imaged. During this time, participants sat quietly and viewed a movie of their choice under controlled laboratory illumination of approximately 5 lux (LX1330B Digital Illuminance Light Meter; Shenzhen Thousandshores Technology, Shenzhen, China). The movie was projected in black and white to avoid any confounding factors related to spectral composition. The participants sat in a rolling chair to minimize movement required to transition between instruments.

After 10 minutes, optical coherence tomography (OCT, Spectralis; Heidelberg Engineering, Heidelberg, Germany) was used to collect baseline images of each eye. For OCT imaging, participants briefly removed the trial frame and looked into the OCT instrument. Two high resolution, six line 30 $^\circ$ radial scans, centered on the fovea and with enhanced depth imaging, were acquired ([Fig. 2A](#)). For noise reduction, B-scan averaging was set at 16 frames, and scans with less than 24 dB quality were repeated. The OCT images acquired had a digital resolution of 3.5 μm /pixel axially, and transverse scaling was calculated based on ocular biometry. The experimental eye was always imaged first, as it has been suggested that choroid effects could be transient and dissipate after a few minutes. The scans took less than two minutes for both eyes in total.

The trial lens over the experimental eye was then replaced with a lens power that included an additional +3.5 D over the distance correction, 3 D of myopic defocus and 0.5 D to compensate for the 2 m viewing distance. The

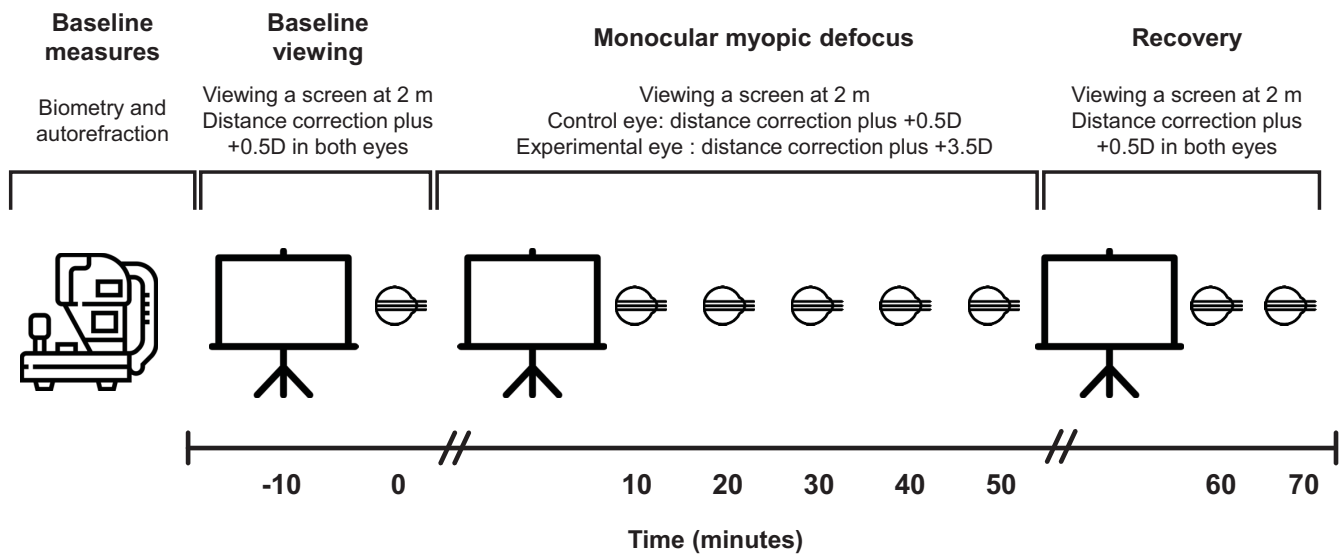


FIGURE 1. Protocol. OCT imaging (eye icon) was performed before and every 10 minutes after monocular imposed myopic defocus for 50 minutes, and then recovery was measured for 20 minutes. For OCT imaging, participants removed the trial frame and looked into the OCT instrument, then replaced the trial frame and again viewed the movie after the scans were captured. Therefore defocus was interrupted for approximately two out of each 10 minutes for OCT imaging.

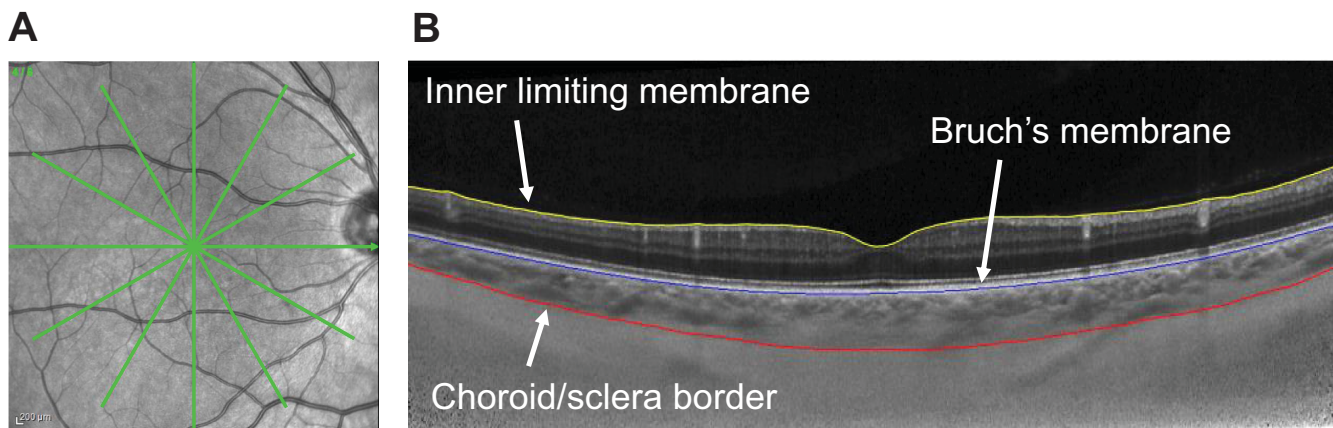


FIGURE 2. (A) Representative infrared fundus image showing the OCT scan protocol (green) and (B) segmentation, including the inner limiting membrane (yellow), Bruch's membrane (blue), and choroid/sclera border (red).

participant continued to watch the movie, and OCT imaging was repeated for each eye every 10 minutes, as described above, for a total of 50 minutes. Following the 50 minute scans, the +3 D defocus was removed from the experimental eye and distance correction (plus +0.5 D) was replaced. Participants continued to watch the movie and final OCT images were collected at 60 and 70 minutes to assess recovery. During each 10 minute distance viewing period, the experimenter was in the room and ensured that the participant was watching the screen and not performing any near work.

OCT images were exported as “*.vol” files.³⁶ B-scans were compensated for light attenuation to enhance the choroid/sclera border.³⁷ The inner limiting membrane was segmented automatically by the Spectralis software. B-scans were further segmented using a neural network to identify the Bruch's membrane and choroid/sclera boundary (Fig. 2B). The neural network was trained using 10,798

manually segmented B-scans, on a Deeplabv3+³⁸ network based on a ResNet50,³⁹ to an accuracy of 99.25% and loss of 0.0229. For accuracy each segmented scan was manually inspected and corrected for errors. The average thickness in the 1-mm diameter region centered at the fovea for the six lines of each radial scan was calculated.

Data Analysis

Within-session repeatability of the automated choroid segmentation was assessed using Bland-Altman analysis of the two right eye scans collected at baseline for each participant, and sample size calculations were carried out in MedCalc (Ostend, Belgium). Statistical analysis was carried out in SPSS version 29 (IBM, Armonk, NY, USA). Data are presented as mean \pm standard error of the mean unless otherwise noted. Spherical equivalent refractive error, axial length, and baseline choroidal thickness between right and

left eyes were assessed with paired *t*-tests. Baseline differences between age groups for spherical equivalent refractive error, axial length, and choroidal thickness of right eyes were assessed with one-way ANOVA and between refractive error groups using unpaired *t*-tests. To assess the effects of monocular myopic defocus on the choroid, changes in choroidal thickness over the 70-minute period were calculated for each eye. A repeated measures ANOVA with two within-subjects factors (condition [defocus or no defocus] and time [in 10-minute intervals]) and one between-subjects factor (age group) was carried out. Post-hoc pairwise comparisons with Bonferroni correction were performed for any variables with significant main effects and interactions. Pearson correlation was used to assess choroidal thickness changes with spherical equivalent refractive error and axial length. Differences were considered significant for $P < 0.05$.

RESULTS

Participants

Forty-eight participants were enrolled in the study. OCT scans were missing at some time points for two participants, a six-year-old and a 32-year-old. This may have been due to OCT images not being saved appropriately. Therefore 46 participants were included in the analysis. Participant demographics are shown in Table 1. Mean age was 25.4 ± 11.2 years and included 23 females and 23 males. Spherical equivalent refractive error ($P = 0.44$), axial length ($P = 0.22$), and choroidal thickness ($P = 0.64$) were not significantly different between right and left eyes. Mean standard deviation of the five axial length measurements for right eyes of each participant was 0.016 ± 0.01 mm. For the entire group, mean spherical equivalent refractive error of right eyes was -1.27 ± 2.11 D (range -7.30 to $+2.07$ D) and mean axial length was 24.21 ± 1.23 mm (range 21.29 – 27.08 mm). Two-way ANOVA showed that baseline choroidal thickness was significantly thinner in the myopic group compared to the nonmyopic group ($P = 0.001$). Post-hoc pairwise compar-

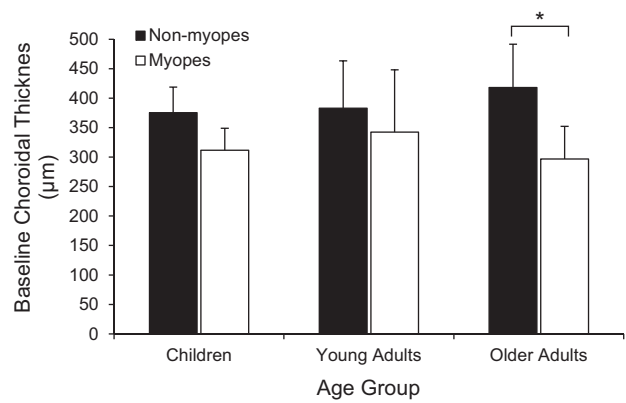


FIGURE 3. Baseline choroidal thickness (mean \pm SD) of right eyes by age group and refractive error group, * $P < 0.05$ for post-hoc pairwise comparisons between refractive error groups.

isons showed that the difference in baseline choroidal thickness was significantly different between the myopic and nonmyopic groups for older adults ($P < 0.01$). There were no significant differences in baseline choroidal thickness between age groups ($P = 1$, Fig. 3).

Of the 4416 images that were segmented automatically and manually inspected, choroidal thickness for one scan was identified as an outlier, and four scans required manual correction. Bland-Altman analysis for within-session repeatability of choroidal thickness is shown in Figure 4. The mean time between scans 1 and 2, as taken from the time stamp on the OCT instrument, was 30.9 ± 14.2 seconds. The mean difference (\pm standard deviation) between scans was -1.17 ± 10.79 μ m (95% confidence interval from -3.42 to 1.08 μ m); the mean difference was not statistically significant from zero ($P = 0.30$). Upper and lower limits of agreement were 19.98 and -22.33 μ m, respectively. Given the mean difference of 1.17 μ m and standard deviation of 10.79 μ m, sample size to detect a 10 μ m effect with 0.05 alpha and 80% power is $N = 14$. Therefore sample size here is suffi-

TABLE 1. Participant Demographics (Mean \pm SD)

	All Participants (N = 46)	Children (N = 15)	Young Adults (N = 16)	Older Adults (N = 15)
Age (years)	25.4 \pm 11.2	12.1 \pm 2.3	26.0 \pm 2.2	38.0 \pm 5.5
Sex				
Male	23	7	8	8
Female	23	8	8	7
Refractive error group				
Nonmyopes	23	9	7	7
Myopes	23	6	9	8
Spherical equivalent refractive error (D)				
OD	-1.27 \pm 2.11	-0.86 \pm 2.15	-1.48 \pm 2.20	-1.46 \pm 2.07
OS	-1.32 \pm 2.13	-0.88 \pm 2.32	-1.66 \pm 2.22	-1.42 \pm 1.88
P value	0.44	0.93	0.08	0.75
Baseline axial length (mm)				
OD	24.21 \pm 1.23	23.61 \pm 1.35	24.56 \pm 1.13	24.42 \pm 1.04
OS	24.17 \pm 1.25	23.54 \pm 1.37	24.57 \pm 1.13	24.37 \pm 0.96
P value	0.22	0.26	0.82	0.33
Baseline choroidal thickness (μ m)				
OD	355 \pm 79	350 \pm 51	360 \pm 95	353 \pm 88
OS	351 \pm 80	352 \pm 73	360 \pm 82	342 \pm 90
P value	0.58	0.80	0.98	0.33

P values are for paired *t*-tests for right and left eyes.

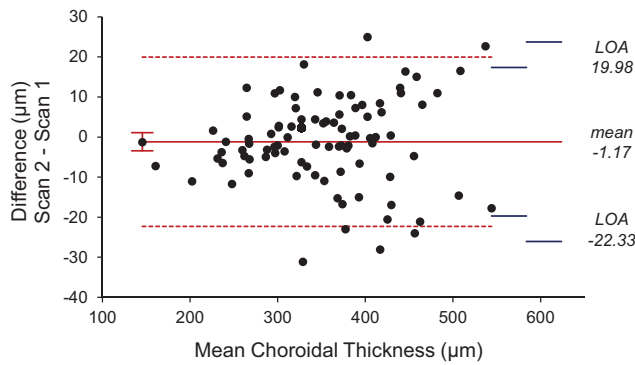


FIGURE 4. Bland-Altman analysis for assessment of within-session repeatability for choroidal thickness. *Solid red line* represents the mean difference between the two scans collected at baseline for each participant; *dashed red line* represents the limits of agreement, and *blue lines* represent the inner and outer 97.5% confidence limits for the limits of agreement.⁴⁰

cient to examine age group and refractive error group differences. The full sample size of 46 is sufficient to detect a 5 μm effect of defocus with 0.05 alpha and 85% power. Additionally, repeatability was assessed by comparing the two consecutive scans at each time point for each participant. In assessing 735 pairs, the mean absolute difference between the two scans was $6.7 \pm 6.6 \mu\text{m}$. Of the 735 pairs, 31 (4.2%) had a difference greater than 20 μm and 12 (1.6%) had a difference greater than 30 μm .

Defocus Effects

Choroidal thickness and choroidal thickness change for each time point are shown for all participants in [Figure 5](#). For the entire population, there was no main effect of condition (experimental versus control) by time over 70 minutes, which included 50 minutes of +3 D monocular defocus in the experimental eye, then 20 minutes of recovery ($F(7, 315) = 0.94, P = 0.47$); that is, choroidal thickness did not significantly change over the 50 minutes of defocus or 20 minutes of recovery for either eye. When age group was considered (children, young adults, older adults), there were also no

significant changes in choroidal thickness over time ($F(2, 43) = 1.62, P = 0.21$).

An additional analysis was performed to examine data from participants in which the two OCT scans at each time point were within 20 μm for all eight time points of both eyes. For this subset of 35 participants, there was also no main effect of condition by time, i.e. the two eyes were not significantly different over the experimental period ($F(7, 238) = 0.53, P = 0.81$).

Refractive error group characteristics are shown in [Table 2](#). Twenty-three participants were classified as nonmyopic, with SER of $+0.31 \pm 0.58$ D in the right eye and 0.27 ± 0.65 D in the left eye, and 23 participants were myopic, with SER of -2.85 ± 1.89 D in the right eye and -2.91 ± 1.88 D in the left eye. SER and axial length of right eyes were significantly different between groups ($P < 0.001$ for both), and baseline choroidal thickness was significantly greater in the nonmyopic group ($390 \pm 65 \mu\text{m}$) than the myopic group ($318 \pm 76 \mu\text{m}, P = 0.001$). Similar to the whole population, there were no significant changes in choroidal thickness over time from baseline or between experimental and control eyes for either refractive error group ($F(7, 308) = 0.88, P = 0.52$).

Choroidal thickness changes were further examined by spherical equivalent refractive error and by axial length using Pearson correlations. There were no significant correlations with spherical equivalent refractive error ($r = 0.11, P = 0.44$) or axial length ($r = -0.14, P = 0.35$).

Discussion

This study aimed to investigate age-related and refractive error group effects of 50 minutes of optically induced full-field myopic defocus on choroidal thickness. Our findings demonstrate that the choroid of children and adults, whether nonmyopic or myopic, does not significantly change in response to short duration full-field myopic defocus as measured in our sample using the described protocol.

Several studies have demonstrated that the choroid in young adults thickens when exposed to short-term myopic defocus (or, correspondingly, that axial length decreases); however, several studies report no significant choroidal thickness or axial length changes to myopic defocus. See [Table 3](#) for a summary of the literature. Chiang et al.⁴¹

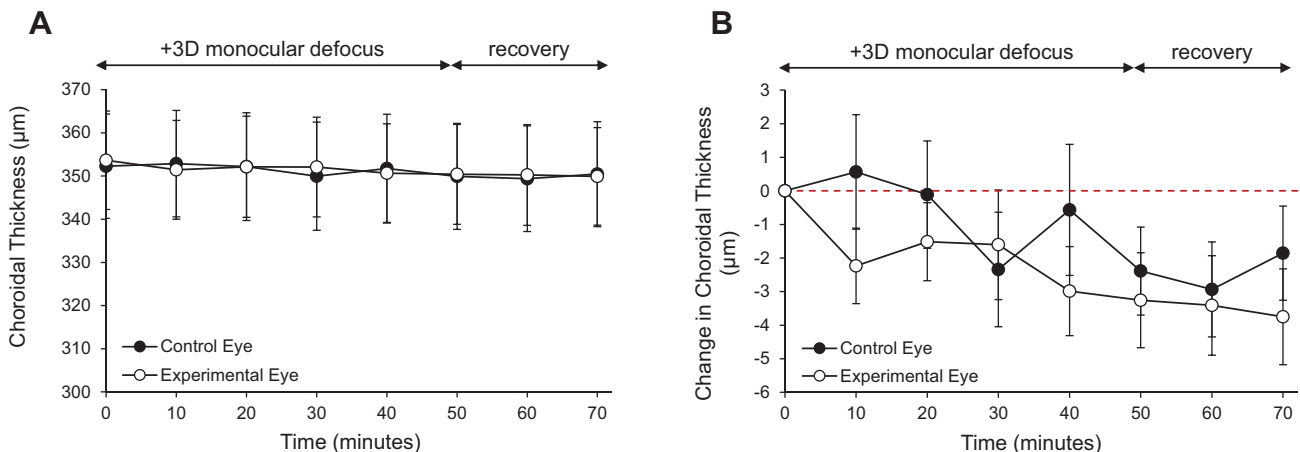


FIGURE 5. (A) Choroidal thickness and (B) change in choroidal thickness over time for control eyes (*filled symbols*) and experimental eyes (*open symbols*) for all participants ($N = 46$); *red dashed line* represents zero change.

TABLE 2. Participant Demographics (Mean \pm SD) for the NonMyopic (N = 23) and Myopic (N = 23) Groups

	NonMyopes (N = 23)	Myopes (N = 23)	P
Age (years)	23.1 \pm 10.9 (8–44)	27.7 \pm 11.2 (11–45)	0.16*
Sex			0.76†
Male	11	12	
Female	12	11	
Spherical equivalent refractive error (D)			<0.001*
OD	+0.31 \pm 0.58	–2.85 \pm 1.89	
OS	+0.27 \pm 0.65	–2.91 \pm 1.88	
Baseline axial length (mm)			<0.001*
OD	23.54 \pm 0.89	24.87 \pm 1.17	
OS	23.47 \pm 0.92	24.87 \pm 1.15	
Baseline choroidal thickness (μ m)			0.001*
OD	390 \pm 65	318 \pm 76	
OS	393 \pm 59	310 \pm 78	

* Unpaired *t*-tests between groups† χ^2 test.

reported approximately 20 μ m of choroidal thickening with +2 D myopic defocus at 60 minutes in both myopic and nonmyopic young adults. Similarly, Read et al.⁴² and Delshad et al.²⁰ reported an 8 to 13 μ m decrease in axial length following 40 to 60 minutes of +3 D myopic defocus in both myopic and emmetropic young adults; it is assumed that transient decreases in axial length correspond to increases in choroidal thickness. However, another study by the same group reported no significant change in axial length after 60 minutes of +3 D myopic defocus.²⁶ Interestingly, Swiatczak and Schaeffel²⁸ reported that the choroidal response to myopic defocus occurred only in emmetropic individuals and not in myopic individuals. Specifically, the study found that emmetropic eyes experienced a decrease in axial length of 9 μ m with +2.5 D defocus, whereas myopic eyes experienced an increase in axial length of 9 μ m. The source of conflicting findings is unclear, although there is a wide variation in experimental protocols and analysis methods across studies. As shown in Table 3, some authors used a cold mirror to simultaneously measure choroidal thickness while the participant still viewed the defocused target. It is possible that, had a cold mirror setup been used here rather than removing the defocus lenses for OCT imaging, a significant change may have been observed. Additionally, there are differences between studies regarding segmentation techniques (manual vs. semi-automated vs. fully automated).

To date, only one study has reported this transient phenomenon in children. Wang et al.⁴³ showed that myopic schoolchildren exposed to +3 D myopic defocus demonstrated a significant decrease in axial length and significant thickening of the choroid thickening of approximately 5 μ m compared to control eyes. However, this thickening was only observed after two hours of exposure and not at one hour. The current study found no effect of myopic defocus after 50 minutes for either adults or children, whether myopic or nonmyopic. Future studies should consider longer exposure periods to better understand the response of the choroid to defocus.

The choroid is suggested to be highly dynamic, responding quickly to a variety of physiological and optical stimuli.²⁹ Changes can be transient and small in amplitude relative to the total thickness of the choroid. Previous studies report an average choroidal thickness of about 200 to 400 μ m, depending on age and refractive error.^{50–54} In the current study, mean baseline choroidal thickness (355 \pm 79 μ m for right

eyes) was similar to ranges reported in previous studies. Additionally, as reported previously,⁵⁵ there was a significant difference in baseline choroidal thickness between refractive error groups, with the myopic group having a thinner choroid than the nonmyopic group.

Because the choroid undergoes diurnal changes in thickness, the time of day when experiments are conducted must be controlled for.³¹ The current study was carried out between 8:00 AM and 11:00 AM. The normal diurnal variation would predict a modest choroidal thinning of approximately 5.0 μ m over this three-hour observational period.³¹ Over the 70 minutes in which choroidal thickness was measured here, a trend in both eyes for choroidal thinning was evident, although not statistically significant. Considering diurnal variations, a previous study found that the choroidal response to defocus varies with the time of day that the defocus is imposed.^{46,56} A study in young adults showed that myopic defocus caused greater choroidal thickening when imposed in the evening compared to the morning.⁴⁶ The authors suggested that a potential interaction between the eye's diurnal rhythms and visual signals exists. In the current study, the choroid response to defocus was only measured in the morning. Therefore, if the response is attenuated in the morning, as the previous study suggested, this may explain why a significant thickening was not observed. Future studies with imposed defocus at different times of the day and for various durations may provide insight into when myopic defocus may be more effective at inducing choroidal thickness changes.

Measuring choroidal thickness changes can be challenging, given that choroidal thickness changes to imposed defocus, when observed, have been on the order of only 5 to 20 μ m.^{41,43,44,57} We aimed to minimize confounding variables that might affect choroidal thickness to investigate changes that are due only to optical defocus. Short-term variables, such as time of day,³¹ caffeine intake,^{58,59} exercise,⁶⁰ intensity and spectral composition of light,^{32,34} and accommodation,⁶¹ have been shown to effect choroidal thickness. Furthermore the choroid undergoes pulsatile changes in thickness associated with heartbeat that add to variation when capturing static images.⁶² Time of day can account for up to 30 μ m of change in choroidal thickness,³¹ so all data collection was restricted to 8:00 AM to 11:00 AM. Chronotype of each participant was not measured and therefore may have contributed to slight variation in choroidal thick-

TABLE 3. Summary of the Literature in Which Choroidal Thickness (Or Axial Length) Changes in Response to Short-Term Myopic Defocus Were Investigated

	Population	Protocol	Task During Defocus	Results
Read et al., 2010 ⁴²	28 emmetropic and myopic young adults	Imposed spectacle lens defocus of +3 D for 60 minutes, axial length measured at 20 and 60 minutes, choroid derived from LenStar peaks	Participants watched a movie on a distance screen	Choroidal thickness significantly increased 12 μ m \pm 16 μ m
		Imposed contact lens defocus of +2 D for 60 minutes, OCT imaging every 5 minutes, manual segmentation	Participants watched a movie on a distance screen	Choroidal thickness significantly increased approx. 20 μ m
Chiang et al., 2015 ⁴¹	12 emmetropic and myopic young adults	Imposed spectacle lens defocus of +3 D for 2 hours, OCT imaging at 1 and 2 hours, manual segmentation	Children watched a television at distance	Choroidal thickness significantly increased approx. 5 μ m only after 2 hours
Wang et al., 2016 ⁴³	17 myopic schoolchildren	Imposed spectacle lens defocus of +2 D for 60 minutes, OCT imaging every 20 minutes, manual segmentation	Participants watched a movie on a distance screen	Choroidal thickness significantly increased 10 \pm 5 μ m
Chiang et al., 2018 ⁴⁴	27 emmetropic and myopic presbyopic adults	Imposed spectacle lens defocus of +3 D for 60 minutes, OCT imaging at 30 and 60 minutes, manual segmentation	Binocular distance viewing	Choroidal thickness significantly increased 12 \pm 3
Sander et al., 2018 ⁴⁵	30 emmetropic and myopic young adults	Imposed spectacle lens defocus of +3 D for two hours in the morning and in the evening, OCT imaging, automatic segmentation with manual adjustment	Participants went about their normal daily activities for the duration of the 2-hour defocus period	Choroidal thickness significantly increased 7 \pm 6 μ m in the morning and 27 \pm 6 μ m in the evening
Moderiano et al., 2019 ⁴⁶	12 near-emmetropic young adults	Imposed contact lens defocus of +2.50, OCT imaging at 30 minutes, automatic segmentation	Participants viewed a fixation arrow displayed at the center of an LCD screen imaged at optical infinity through a 13 D Badal lens and a cold mirror	Choroidal thickness significantly increased compared to the control group (2 \pm 8 μ m, $P = 0.02$)
Hoseini-Yazdi et al., 2019 ⁴⁷	25 emmetropic and myopic young adults	Imposed spectacle lens defocus of +3 D for 60 minutes, OCT imaging with cold mirror every 20 minutes, semi-automatic segmentation	Participants watched a movie on a distance screen	Choroidal thickness significantly increased 8 \pm 5 μ m
Hoseini-Yazdi et al., 2020 ⁴⁸	18 emmetropic and myopic young adults	Calculated low pass filtering of movie to equal +2.5 D and imposed spectacle lens defocus of +2.5 D, axial length measured at 60 minutes	Participants watched a movie on a distance screen	Axial length of emmetropic eyes shortened $-8.8 \pm 9.2 \mu$ m (myopic eyes increased, see below)*
Swiatczak et al., 2021 ²⁸	20 emmetropic and myopic young adults	Imposed optical defocus of +2.50 D for 30 minutes, axial length measured at 30 minutes	Participants watched a movie on a distance screen	Axial length of emmetropic eyes shortened approx. 8 μ m compared to control eyes*
Swiatczak et al., 2023 ⁴⁹	18 emmetropic and myopic young adults	Imposed optical defocus of +2.50 D for 30 minutes, axial length measured at 30 minutes	Participants watched a movie on a distance screen	Axial length of emmetropic eyes shortened approx. 8 μ m compared to control eyes*
Studies finding NO significant thickening of the choroid or decrease in axial length with myopic defocus				
Breher et al., 2018 ⁵	18 myopic young adults	Imposed contact lens defocus of +2.50, OCT imaging with automatic segmentation	Participants watched a movie on a distance screen	No significant changes in choroidal thickness
Delshad et al., 2021 ²⁶	16 emmetropic and myopic young adults	Imposed spectacle lens defocus of +3 D for 60 minutes, OCT imaging with cold mirror at 60 minutes, semi-automatic segmentation	Participants watched a movie on a distance screen	No significant changes in choroidal thickness
Swiatczak et al., 2021 ²⁸	20 emmetropic and myopic young adults	Imposed spectacle lens defocus of +3 D for 60 minutes, OCT imaging every 7.5-15 minutes, manual segmentation of OCT	Participants watched a movie on a distance screen	Axial length of myopic eyes increased 9.1 \pm 11.2 μ m (emmetropic eyes decreased, see above)*
Current study	48 emmetropic and myopic children and young adults	Calculated low pass filtering of movie to equal +2.5 D and imposed spectacle lens defocus of +2.5 D, LenStar measurements for axial length	Participants watched a movie on a distance screen	No significant changes in choroidal thickness

Note that some of these studies had other conditions in the article, but only the full field-positive defocus conditions are included here.

* Axial length was measured as a surrogate for choroidal thickness; decreased axial length assumes increased choroidal thickness.

ness. Some studies have shown that drinking a cup of coffee can cause thinning of the choroid for up to four hours after ingestion.⁵⁹ Therefore we asked subjects to refrain from caffeine-containing drinks and foods the morning of the experiment. Exercise has also been shown to increase choroidal thickness within five minutes.⁶⁰ Participants were asked to avoid vigorous physical activity the morning of the experiment and to sit in a chair during the experimental session. The OCT instrument was located directly next to the participants, so that they stayed seated and simply rolled the chair to the instrument at each time point. Ma et al.⁶³ showed the choroid response to myopic defocus was present with ambient illumination of 10 lux, but not with 1000 lux. Therefore the lights were dimmed in the room to 5 lux, with the projector screen providing the main source of illumination. To minimize the effects of accommodation, subjects viewed a distant target during the experiment and were asked to avoid any near work during the session, including hand held electronic devices, as a previous study showed that after 10 minutes of focusing on a 6 D stimulus for accommodation, the choroid thinned by 5 μm subfoveally.⁶¹ OCT images were always collected for the experimental eye first, followed by the control eye. On average, these measurements took no more than two minutes. Despite using strictly controlled protocols, no significant changes in choroidal thickness were observed over the experimental session.

Speculation exists whether short-term choroidal thickness changes are indicative of the treatment effect of optical control strategies for myopia in children. Current optical treatments of myopia include bifocal and progressive addition lenses, soft multifocal lenses, orthokeratology, and incorporated plus lenslets in spectacle lenses. Several studies have shown that these treatment lenses induce choroidal thickening.^{64,65} One of the goals of the current study was to replicate previous findings that myopic full-field defocus induces choroidal thickening in children and adults while carefully controlling for confounding factors and using objective image analysis techniques. However, we failed to observe choroidal thickening with myopic defocus. Not all previously published studies have reported choroidal thickening to 30 to 60 minutes full-field defocus. As discussed above, Wang et al.⁴³ found a myopic-defocus induced choroidal thickening in children only after two hours of exposure but not after one hour. Kuombo et al.⁶⁶ assessed choroidal thickness in 10 adults after 30 minutes of full-field myopic defocus, full-field hyperopic defocus, and a multifocal distance center contact lens with a 2.5 D add power. The authors found a small increase in choroidal thickness with full-field myopic defocus in the inferior field only, and for the multifocal lens, a small increase in the superior field only. In contrast to other studies, Swiatczak and Schaeffel²⁸ reported that axial length increased (rather than decreased) with myopic defocus in myopic individuals, likely representing a thinning of the choroid. Another group reported significant choroidal thickening to myopic defocus in some studies,^{42,67} but not in others.²⁶ The small and inconsistent changes in the choroid with myopic defocus across studies may be due to variations in population characteristics, protocols, and quantification methods and suggests that it is difficult to elicit robust changes in the human choroid.

Limitations of the current study include the following. The trial frame was removed to capture OCT images every 10 minutes, thereby interrupting the defocus. Although the OCT imaging took less than two minutes, it is possible that effects on the choroid may have started to dissipate. Cyclo-

plegia was not used for refractive error measurement. This was done to avoid confounding effects of antimuscarinic agents on the choroid.²⁹ However, an open-field autorefractor with a distant target was used to minimize proximal accommodation cues and to promote ciliary muscle relaxation. The order in which the eyes were measured was not randomized. This was done so that the experimental eye was always measured first and within the shortest amount of time. Effects of defocus on the choroid were only measured for 50 minutes, whereas longer exposures may be necessary to observe significant changes in the choroid. Additionally, only full-field defocus was investigated here; full-field defocus is not reflective of partial defocus optical profile used in current myopia treatments, such as bifocals, orthokeratology, and soft multifocal lenses. Finally, participants watched a movie at a distance of 2 m during the experimental session, which does not stimulate day-to-day habitual viewing patterns of the near and distant visual environment. Therefore these experiments performed in a laboratory setting do not fully reflect real-world application of defocus in myopia treatment.

In conclusion, this study showed that myopic and nonmyopic children and adults do not demonstrate transient choroidal thickening in response to imposed myopic defocus as evaluated in our lab. We controlled numerous variables, including time of day, caffeine intake, physical activity, ambient illumination, and viewing distance, and objective automated choroid segmentation techniques were used. These findings are in contrast with some previously published reports and raise questions regarding the utility of using choroidal thickness changes as a short-term biomarker when evaluating potential efficacy of myopia control treatments.

Acknowledgments

Supported by the University of Houston Mary Murphy Endowment, NIH NEI R01 EY030193, and P30 EY007551.

Disclosure: **L.A. Ostrin**, Meta (F), Vyluma (C), Zeiss (C, P); **R.P. Sah**, None; **H.M. Queener**, None; **N.B. Patel**, None; **R. Tran**, None; **D Shukla**, None; **H. Mirhajianmoghadam**, None

References

- Holden BA, Fricke TR, Wilson DA, et al. Global prevalence of myopia and high myopia and temporal trends from 2000 through 2050. *Ophthalmology*. 2016;123:1036–1042.
- Saw SM, Gazzard G, Shih-Yen EC, Chua WH. Myopia and associated pathological complications. *Ophthalmic Physiol Opt*. 2005;25:381–391.
- Grodum K, Heijl A, Bengtsson B. Refractive error and glaucoma. *Acta Ophthalmol Scand*. 2001;79:560–566.
- Lim R, Mitchell P, Cumming RG. Refractive associations with cataract: the Blue Mountains Eye Study. *Invest Ophthalmol Vis Sci*. 1999;40:3021–3026.
- Polkinghorne PJ, Craig JP. Northern New Zealand Rhegmatogenous Retinal Detachment Study: epidemiology and risk factors. *Clin Exp Ophthalmol*. 2004;32:159–163.
- Naidoo KS, Fricke TR, Frick KD, et al. Potential lost productivity resulting from the global burden of myopia: systematic review, meta-analysis, and modeling. *Ophthalmology*. 2019;126:338–346.
- Gwiazda J, Hyman L, Hussein M, et al. A randomized clinical trial of progressive addition lenses versus single vision

- lenses on the progression of myopia in children. *Invest Ophthalmol Vis Sci.* 2003;44:1492–1500.
8. Walline JJ, Walker MK, Mutti DO, et al. Effect of high add power, medium add power, or single-vision contact lenses on myopia progression in children: the BLINK Randomized Clinical Trial. *JAMA.* 2020;324:571–580.
 9. Li X, Huang Y, Yin Z, et al. Myopia control efficacy of spectacle lenses with aspherical lenslets: results of a 3-year follow-up study. *Am J Ophthalmol.* 2023;253:160–168.
 10. Lam CSY, Tang WC, Tse DY, et al. Defocus Incorporated Multiple Segments (DIMS) spectacle lenses slow myopia progression: a 2-year randomised clinical trial. *Br J Ophthalmol.* 2020;104:363–368.
 11. Gardner DJ, Walline JJ, Mutti DO. Choroidal thickness and peripheral myopic defocus during orthokeratology. *Optom Vis Sci.* 2015;92:579–588.
 12. Chen Y, Shen X. Compensatory changes in the anterior segment and vascular system of the eye in myopic children after orthokeratology. *Front Pediatr.* 2021;9:663644.
 13. Breher K, Garcia MG, Ohlendorf A, Wahl S. The effect of the optical design of multifocal contact lenses on choroidal thickness. *PLoS One.* 2018;13:e0207637.
 14. Zhu X, Park TW, Winawer J, Wallman J. In a matter of minutes, the eye can know which way to grow. *Invest Ophthalmol Vis Sci.* 2005;46:2238–2241.
 15. Wallman J, Wildsoet C, Xu A, et al. Moving the retina: choroidal modulation of refractive state. *Vision Res.* 1995;35:37–50.
 16. Howlett MH, McFadden SA. Spectacle lens compensation in the pigmented guinea pig. *Vision Res.* 2009;49:219–227.
 17. Metlapally S, McBrien NA. The effect of positive lens defocus on ocular growth and emmetropization in the tree shrew. *J Vis.* 2008;8:11–12.
 18. Troilo D, Nickla DL, Wildsoet CF. Choroidal thickness changes during altered eye growth and refractive state in a primate. *Invest Ophthalmol Vis Sci.* 2000;41:1249–1258.
 19. Hung LF, Wallman J, Smith EL, 3rd. Vision-dependent changes in the choroidal thickness of macaque monkeys. *Invest Ophthalmol Vis Sci.* 2000;41:1259–1269.
 20. Delshad S, Collins MJ, Read SA, Vincent SJ. The time course of the onset and recovery of axial length changes in response to imposed defocus. *Sci Rep.* 2020;10:8322.
 21. Wu H, Chen W, Zhao F, et al. Scleral hypoxia is a target for myopia control. *Proc Natl Acad Sci USA.* 2018;115:E7091–E7100.
 22. Fitzgerald ME, Wildsoet CF, Reiner A. Temporal relationship of choroidal blood flow and thickness changes during recovery from form deprivation myopia in chicks. *Exp Eye Res.* 2002;74:561–570.
 23. Nickla DL, Wallman J. The multifunctional choroid. *Prog Retin Eye Res.* 2010;29:144–168.
 24. Ramrattan RS, van der Schaft TL, Mooy CM, de Bruijn WC, Mulder PG, de Jong PT. Morphometric analysis of Bruch's membrane, the choriocapillaris, and the choroid in aging. *Invest Ophthalmol Vis Sci.* 1994;35:2857–2864.
 25. Amorim-de-Sousa A, Paune J, Silva-Leite S, Fernandes P, Gozalez-Meijome JM, Queiros A. Changes in choroidal thickness and retinal activity with a myopia control contact lens. *J Clin Med.* 2023;12:3618.
 26. Delshad S, Collins MJ, Read SA, Vincent SJ. Effects of brief periods of clear vision on the defocus-mediated changes in axial length and choroidal thickness of human eyes. *Ophthalmic Physiol Opt.* 2021;41:932–940.
 27. Kubota R, Joshi NR, Samandarova I, et al. Effect of short-term peripheral myopic defocus on ocular biometrics using Fresnel “press-on” lenses in humans. *Sci Rep.* 2021;11:22690.
 28. Swiatczak B, Schaeffel F. Emmetropic, but not myopic human eyes distinguish positive defocus from calculated blur. *Invest Ophthalmol Vis Sci.* 2021;62:14.
 29. Ostrin LA, Harb E, Nickla DL, et al. IMI—The dynamic choroid: new insights, challenges, and potential significance for human myopia. *Invest Ophthalmol Vis Sci.* 2023;64:4.
 30. Ostrin LA, Jnawali A, Carkeet A, Patel NB. Twenty-four hour ocular and systemic diurnal rhythms in children. *Ophthalmic Physiol Opt.* 2019;39:358–369.
 31. Burfield HJ, Patel NB, Ostrin LA. Ocular biometric diurnal rhythms in emmetropic and myopic adults. *Invest Ophthalmol Vis Sci.* 2018;59:5176–5187.
 32. Read SA, Pieterse EC, Alonso-Caneiro D, et al. Daily morning light therapy is associated with an increase in choroidal thickness in healthy young adults. *Sci Rep.* 2018;8:8200.
 33. Lou L, Ostrin LA. The outdoor environment affects retinal and choroidal thickness. *Ophthalmic Physiol Opt.* 2023;43:572–583.
 34. Lou L, Ostrin LA. Effects of narrowband light on choroidal thickness and the pupil. *Invest Ophthalmol Vis Sci.* 2020;61:40.
 35. Thakur S, Dhakal R, Verkicharla PK. Short-term exposure to blue light shows an inhibitory effect on axial elongation in human eyes independent of defocus. *Invest Ophthalmol Vis Sci.* 2021;62:22.
 36. Sullivan-Mee M, Patel NB, Pensyl D, Qualls C. Relationship between juxtapapillary choroidal volume and beta-zone parapapillary atrophy in eyes with and without primary open-angle glaucoma. *Am J Ophthalmol.* 2015;160:637–647.e631.
 37. Girard MJ, Strouthidis NG, Ethier CR, Mari JM. Shadow removal and contrast enhancement in optical coherence tomography images of the human optic nerve head. *Invest Ophthalmol Vis Sci.* 2011;52:7738–7748.
 38. Chen L, Zhu Y, Papandreou G, Schroff F, Adam H. Encoder-decoder with atrous separable convolution for semantic image segmentation. *Computer Vision.* 2018;ECCV 18.
 39. Kaiming H, Zhang X, Ren S, Sun J. Deep residual learning for image recognition. *Proc IEEE Conf Comput Vis Pattern Recognit.* 2016;8:777–778.
 40. Carkeet A. Exact parametric confidence intervals for Bland-Altman limits of agreement. *Optom Vis Sci.* 2015;92:e71–e80.
 41. Chiang ST, Phillips JR, Backhouse S. Effect of retinal image defocus on the thickness of the human choroid. *Ophthalmic Physiol Opt.* 2015;35:405–413.
 42. Read SA, Collins MJ, Sander BP. Human optical axial length and defocus. *Invest Ophthalmol Vis Sci.* 2010;51:6262–6269.
 43. Wang D, Chun RK, Liu M, et al. Optical defocus rapidly changes choroidal thickness in schoolchildren. *PLoS one.* 2016;11:e0161535.
 44. Chiang ST, Chen TL, Phillips JR. Effect of optical defocus on choroidal thickness in healthy adults with presbyopia. *Invest Ophthalmol Vis Sci.* 2018;59:5188–5193.
 45. Sander BP, Collins MJ, Read SA. The interaction between homatropine and optical blur on choroidal thickness. *Ophthalmic Physiol Opt.* 2018;38:257–265.
 46. Moderiano D, Do M, Hobbs S, et al. Influence of the time of day on axial length and choroidal thickness changes to hyperopic and myopic defocus in human eyes. *Exp Eye Res.* 2019;182:125–136.
 47. Hoseini-Yazdi H, Vincent SJ, Collins MJ, Read SA. Regional alterations in human choroidal thickness in response to short-term monocular hemifield myopic defocus. *Ophthalmic Physiol Opt.* 2019;39:172–182.
 48. Hoseini-Yazdi H, Vincent SJ, Read SA, Collins MJ. Astigmatic defocus leads to short-term changes in human choroidal thickness. *Invest Ophthalmol Vis Sci.* 2020;61:48.
 49. Swiatczak B, Schaeffel F, Calzetti G. Imposed positive defocus changes choroidal blood flow in young human subjects. *Graefes Arch Clin Exp Ophthalmol.* 2023;261:115–125.

50. Ikuno Y, Kawaguchi K, Nouchi T, Yasuno Y. Choroidal thickness in healthy Japanese subjects. *Invest Ophthalmol Vis Sci.* 2010;51:2173–2176.
51. Copete S, Flores-Moreno I, Montero JA, Duker JS, Ruiz-Moreno JM. Direct comparison of spectral-domain and swept-source OCT in the measurement of choroidal thickness in normal eyes. *Br J Ophthalmol.* 2014;98:334–338.
52. Read SA, Collins MJ, Vincent SJ, Alonso-Caneiro D. Choroidal thickness in childhood. *Invest Ophthalmol Vis Sci.* 2013;54:3586–3593.
53. Wei WB, Xu L, Jonas JB, et al. Subfoveal choroidal thickness: the Beijing Eye Study. *Ophthalmology.* 2013;120:175–180.
54. Hoseini-Yazdi H, Vincent SJ, Collins MJ, Read SA, Alonso-Caneiro D. Wide-field choroidal thickness in myopes and emmetropes. *Sci Rep.* 2019;9:3474.
55. Sogawa K, Nagaoka T, Takahashi A, et al. Relationship between choroidal thickness and choroidal circulation in healthy young subjects. *Am J Ophthalmol.* 2012;153:1129–1132.e1121.
56. Nickla DL, Jordan K, Yang J, Totonelly K. Brief hyperopic defocus or form deprivation have varying effects on eye growth and ocular rhythms depending on the time-of-day of exposure. *Exp Eye Res.* 2017;161:132–142.
57. Chakraborty R, Read SA, Collins MJ. Hyperopic defocus and diurnal changes in human choroid and axial length. *Optom Vis Sci.* 2013;90:1187–1198.
58. Dervişoğulları MS, Totan Y, Yüce A, Kulak AE. Acute effects of caffeine on choroidal thickness and ocular pulse amplitude. *Cutan Ocul Toxicol.* 2016;35:281–286.
59. Vural AD, Kara N, Sayin N, Pirhan D, Ersan HB. Choroidal thickness changes after a single administration of coffee in healthy subjects. *Retina.* 2014;34:1223–1228.
60. Sayin N, Kara N, Pekel G, Altinkaynak H. Choroidal thickness changes after dynamic exercise as measured by spectral-domain optical coherence tomography. *Indian J Ophthalmol.* 2015;63:445–450.
61. Woodman-Pieterse EC, Read SA, Collins MJ, Alonso-Caneiro D. Regional changes in choroidal thickness associated with accommodation. *Invest Ophthalmol Vis Sci.* 2015;56:6414–6422.
62. Sayah DN, Mazzaferrri J, Ghesquiere P, et al. Non-invasive in vivo measurement of ocular rigidity: Clinical validation, repeatability and method improvement. *Exp Eye Res.* 2020;190:107831.
63. Ma Y, Bao J, Drobe B, Chen H. The effect of defocus on choroidal thickness in bright and low illuminance. *Invest Ophthalmol Vis Sci.* 2016;57:2483–2483.
64. Hao Q, Zhao Q. Changes in subfoveal choroidal thickness in myopic children with 0.01% atropine, orthokeratology, or their combination. *Int Ophthalmol.* 2021;41:2963–2971.
65. Huang Y, Li X, Wu J, et al. Effect of spectacle lenses with aspherical lenslets on choroidal thickness in myopic children: a 2-year randomised clinical trial. *Br J Ophthalmol.* 2023;107:1806–1822.
66. Kuombo IOM, Conrad F, Sankaridurg P, Ehrmann K. Effects of short-term imposed optical defocus on central and peripheral eye length and choroidal thickness in healthy subjects. *Invest Ophthalmol Vis Sci.* 2019;60:4339–4339.
67. Delshad S, Collins MJ, Read SA, Vincent SJ. The human axial length and choroidal thickness responses to continuous and alternating episodes of myopic and hyperopic blur. *PLoS one.* 2020;15:e0243076.