

Intraocular Pressure While Using Gonioscopy, SLT, and Laser Iridotomy Lenses: An Ex Vivo Study

Ticiana De Francesco,¹⁻³ Eric Mikula,^{4,5} Wes Lummis,⁴ Nathan Sangalang,⁴ and Iqbal Ike K. Ahmed^{1,6}

¹John Moran Eye Center, University of Utah, Salt Lake City, Utah, United States

²Clinica de Olhos De Francesco, Fortaleza, Brazil

³Hospital de Olhos Leiria de Andrade (HOLA), Fortaleza, Brazil

⁴ViaLase Inc., Aliso Viejo, California, United States

⁵Department of Ophthalmology, University of California, Irvine, Irvine, California, United States

⁶Department of Ophthalmology & Vision Sciences, University of Toronto, Toronto, Ontario, Canada

Correspondence: Ticiana De Francesco, Clinica de Olhos De Francesco, 499 Rua Barão de Aracati, Fortaleza, CE 60115-090, Brazil; ticianadefrancesco@gmail.com.

Received: October 24, 2023

Accepted: March 20, 2024

Published: May 7, 2024

Citation: De Francesco T, Mikula E, Lummis W, Sangalang N, Ahmed I. Intraocular pressure while using gonioscopy, SLT, and laser iridotomy lenses: An ex vivo study. *Invest Ophthalmol Vis Sci.* 2024;65(5):13. <https://doi.org/10.1167/iovs.65.5.13>

PURPOSE. The purpose of this study was to measure intraocular pressure (IOP) elevation while applying standard gonioscopy, selective laser trabeculoplasty (SLT), and laser iridotomy procedural lenses.

METHODS. Twelve cadaver eyes were mounted to a custom apparatus and cannulated with a pressure transducer which measured IOP. The apparatus was mounted to a load cell which measured the force on the eye. Six ophthalmologists performed simulated gonioscopy (Sussman 4 mirror lens), SLT (Latina lens), and laser iridotomy (Abraham lens) while a computer recorded IOP (mm Hg) and force (grams). The main outcome measures were IOP and force applied to the eye globe during ophthalmic diagnostics and procedures.

RESULTS. The average IOP's during gonioscopy, SLT, and laser iridotomy were 43.2 ± 16.9 mm Hg, 39.8 ± 9.9 mm Hg, and 42.7 ± 12.6 mm Hg, respectively. The mean force on the eye for the Sussman, Latina, and Abraham lens was 40.3 ± 26.4 grams, 66.7 ± 29.8 grams, and 65.5 ± 35.9 grams, respectively. The average force applied to the eye by the Sussman lens was significantly lower than both the Latina lens ($P = 0.0008$) and the Abraham lens ($P = 0.001$). During gonioscopy indentation, IOP elevated on average to 80.5 ± 22.6 mm Hg. During simulated laser iridotomy tamponade, IOP elevated on average to 82.3 ± 27.2 mm Hg.

CONCLUSIONS. In cadaver eyes, the use of standard ophthalmic procedural lenses elevated IOP by approximately 20 mm Hg above baseline.

Keywords: gonioscopy, selective laser trabeculoplasty (SLT), intraocular pressure (IOP)

Elevated intraocular pressure (IOP) is the primary modifiable risk factor in glaucoma.¹ Reducing IOP is thought to decrease the structural deformation across the lamina cribrosa which in turn reduces damage to retinal ganglion cells, thus preventing further visual field loss.² Similarly, minimizing the incidence and magnitude of the transient IOP elevation is also important to consider in the patients with glaucoma. Specifically, glaucomatous eyes with different biomechanical properties of connective tissues may be particularly sensitive to acute IOP insults when compared to healthy eyes or those with ocular hypertension.^{3,4}

In routine ophthalmic practice, several diagnostic and interventional procedures can potentially elevate IOP. Some of those procedures are of interest for patients with glaucoma, such as the diagnostic examination of gonioscopy which relies on applanating a rigid lens upon the anterior surface of the cornea to visualize the angle structures. Each gonioscopy lens has a specific radius of curvature along the surface which contacts the cornea; this radius

of curvature is typically not a perfect match for the radius of curvature of a particular patient, but rather an average radius suited to the entire population. The average radius of curvature of the adult anterior cornea is 7.8 mm, whereas the radius of common ophthalmic lenses varies from 7.4 mm to 7.8 mm.^{5,6} Because a rigid body (the lens) and a deformable but incompressible body (the eye) need to make tight contact with one another, there is a force generated upon the eye, resulting in a transient IOP increase during the contact.

Because the field began to develop over a century ago,⁷ gonioscopy has become a ubiquitous diagnostic tool of the ophthalmologist, especially for glaucoma. Procedural lenses such as those used during selective laser trabeculoplasty (SLT) and laser iridotomy are also commonly used for glaucoma laser treatment. Despite the use of lenses, which contact the anterior cornea and require a degree of force to maintain the view, the magnitude of the IOP rise is still poorly understood. This may be relevant particu-

larly for those patients who have severe glaucomatous optic neuropathy, although it is uncertain what the clinical significance of this is. The dearth of in vivo data in the literature regarding IOP during gonioscopy is not surprising, given the practical issue that traditional tonometry requires the unobstructed corneal surface for IOP measurement. However, there is also an absence of ex vivo data in the literature regarding IOP during the use of diagnostic and therapeutic lenses. To the best of our knowledge, there are no published studies of the real-time IOP changes during those glaucoma diagnostics and treatment procedures.

The purpose of this study is to measure the IOP and applied force in the ex vivo human eye globe during common ophthalmic diagnostics and procedures which require a lens to contact the eye, namely gonioscopy, SLT, and laser iridotomy. We used a standardized approach that has been used in other similar studies evaluating the degrees of IOP rise with ophthalmic procedures.

METHODS

Measurement Apparatus

A custom device was designed and built to measure IOP and force during lens appplanation on human cadaver globes (Fig. 1). Briefly, a custom syringe activated suction cup was used to hold the eye globe. A fiber optic micro-catheter pressure transducer (FISO Model FOP-LS-PT9-10; FISO, Quebec, Canada) was threaded into a 22-gauge needle which was inserted into the vitreous compartment at the equator of the globe via an access port on the suction cut. The sclera elasticity created a self-sealed incision around the needle and was verified to ensure there were no leaks. The signal from the transducer was routed to a signal conditioner (FISO Model FPI-LS-10, Config F2-SCAI-V). The signal conditioner was mated with a chassis (FISO Evolution Chassis, Model i-EVO_688) which powered the signal conditioner and also served as the digital interface to the personal computer (PC). FISO EVO software was used to record IOP data at a sampling rate of 5 hertz (Hz). The needle containing the pressure transducer was also connected to a water filled pressure reservoir approximately 10.7 inches (approximately 20 mm Hg) above the eye-holder via plas-



FIGURE 2. Examiner holding the lens on the cadaveric globe and elbow resting on the table to simulate a slit lamp table.

tic tubing and a stopcock. The stopcock to the reservoir was opened for 3 to 4 minutes prior to each measurement. This established a baseline IOP of 20 mm Hg inside the globe, as measured by the calibrated pressure transducer. The baseline pressure was chosen to be at the upper range of normal IOP (10–20 mm Hg).⁸ The stopcock was closed during the measurement. The suction cup containing the eye was mounted to a load cell (Model LSB205; Futek Advanced Sensor Technology, Inc., Irvine, CA, USA), which was in turn mounted to a sturdy vertical post and base. The load cell was connected to a Futek USB output kit (Model USB220), which digitally interfaced with the PC. Futek Sensit software recorded load cell data at a 5 Hz sampling rate. The raw mass data (grams) recorded by the loadcell is directly proportional to force; 100 grams is equal to 0.98 Newtons and the results were reported in grams as this was the output of the load cell.

The eye holder was recessed in the artificial face which was oriented to approximate a sitting patient and a table was used to rest the elbow of the seated examiner to simulate a slit lamp table (Fig. 2). Attention was given to ensure as much consistency as possible with the in vivo conditions of the eye.

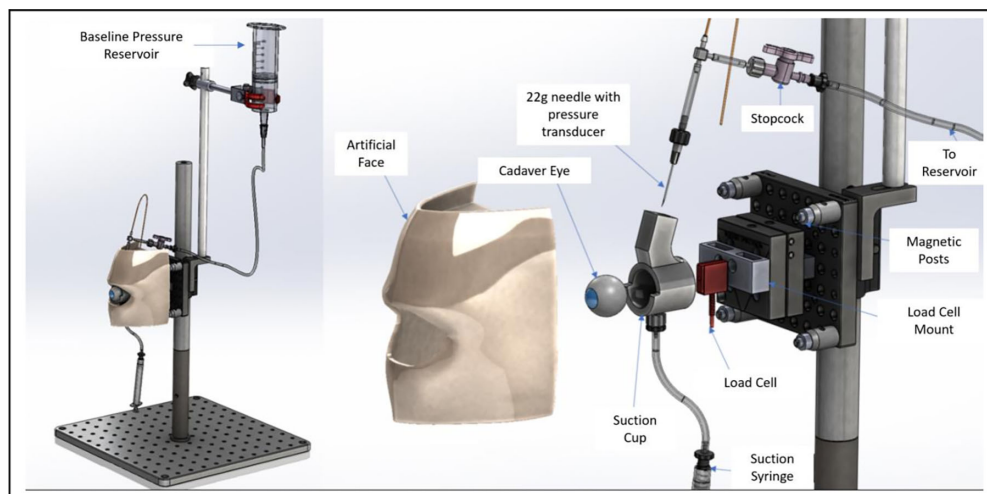


FIGURE 1. Custom apparatus for measuring IOP and force on the eye during gonioscopy, SLT, and laser iridotomy in human cadaver eyes.



FIGURE 3. Images of the lens and schematic showing area of procedural lens/globe. (A) Sussman goniolens. (B) Latina lens. (C) Abraham lens. Images courtesy of Ocular.

Human Tissues

Twelve whole eye globes with no history of glaucoma and not suitable for transplantation were obtained from San Diego Eye Bank within 48 hours of death. Eyes were refrigerated in a moist chamber for no longer than 5 days before use. None of the globes had visible corneal clouding or anatomic abnormalities.

Measurement Protocol

Six glaucoma fellowship trained ophthalmologists participated in the study. Each ophthalmologist simulated gonioscopy, SLT, and laser iridotomy using their dominant and non-dominant hands on 3 separate eyes, for a total of 18 test measurements per ophthalmologist (6 measurements per lens). Gonioscopy, SLT, and laser iridotomy visualization were simulated using a Sussman 4-mirror lens, a Latina SLT lens, and an Abraham lens (Fig. 3), respectively. The radius of curvature and contact diameter of each lens is summa-

TABLE 1. Radius of Curvature and Contact Diameter of Sussman, Latina, and Abraham Lens

	Sussman	Latina	Abraham
Radius of curvature	8.0 mm	7.45 mm	7.45 mm
Contact diameter	8.13 mm	12.25 mm	12.25 mm

rized in Table 1. Ophthalmologists were instructed to apply gonio-gel to the lens before applying the lens to the test eye as they would in a clinical setting. Data from the pressure transducer and load cell were recorded to the computer during each measurement.

Ophthalmologists were instructed to maintain a minimum pressure with the lens to induce appplanation and achieve a clear view, without causing corneal striae. The SLT measurement was performed by rotating the lens the full 360 degrees; all measurements were performed over the course of 1 minute. Furthermore, three ophthalmologists simulated indentation gonioscopy with the Sussman lens while two simulated tamponade with the Abraham lens. A baseline pressure of 20 mm Hg was established via the gravity reservoir between each measurement. The pressure transducer was zeroed before each measurement.

Statistics

The average pressure and force were calculated for each individual measurement (6 measurements per ophthalmologist per lens and 36 measurements per lens), comprising the full time from when the lens was put on the eye to when it was taken off the eye. The mean and standard deviation of each group (lens type) was calculated from these averaged individual measurement values. The minimum and maximum measured values, before averaging, were reported for each lens type. Differences between groups were investigated using analysis of variance (MatLab, Mathworks Inc., Natick, MA, USA). For ease of visualization in Figure 4, data were averaged over 60 seconds for each group. For measurements that went over 60 seconds, the first and last 30 seconds of data were concatenated to normalize measurement time for the figure.

RESULTS

Force and IOP data are summarized in Table 2. The mean age of the eyes in the study was 74.8 ± 15.8 years old (range = 65–94 years). Thirty-five measurements were performed using the Sussman lens, whereas both the Latina and Abraham lenses had 36 measurements. One measurement with the Sussman lens was not recorded due to a software error. The mean IOP's for the Sussman, Latina, and Abraham lenses were 43.2 ± 16.9 mm Hg, 39.8 ± 9.9 mm Hg, and 42.7 ± 12.6 mm Hg, respectively. There was no statistically significant difference in mean IOP among the three lenses (P > 0.05). The box and whisker plot in Figure 5 shows the distribution of IOP among the three lenses. Maximum average pressures during a single measurement were 85.8, 60.9, and 73.2 mm Hg for the Sussman, Latina, and Abraham lenses, respectively. The mean forces on the eye for the Sussman, Latina, and Abraham lenses were 40.3 ± 26.4 grams, 66.7 ± 29.8 grams, and 65.5 ± 35.9 grams, respectively. As expected, force applied to the eye was directly proportional to the IOP (Fig. 6). The average force exerted on the eye by the Suss-

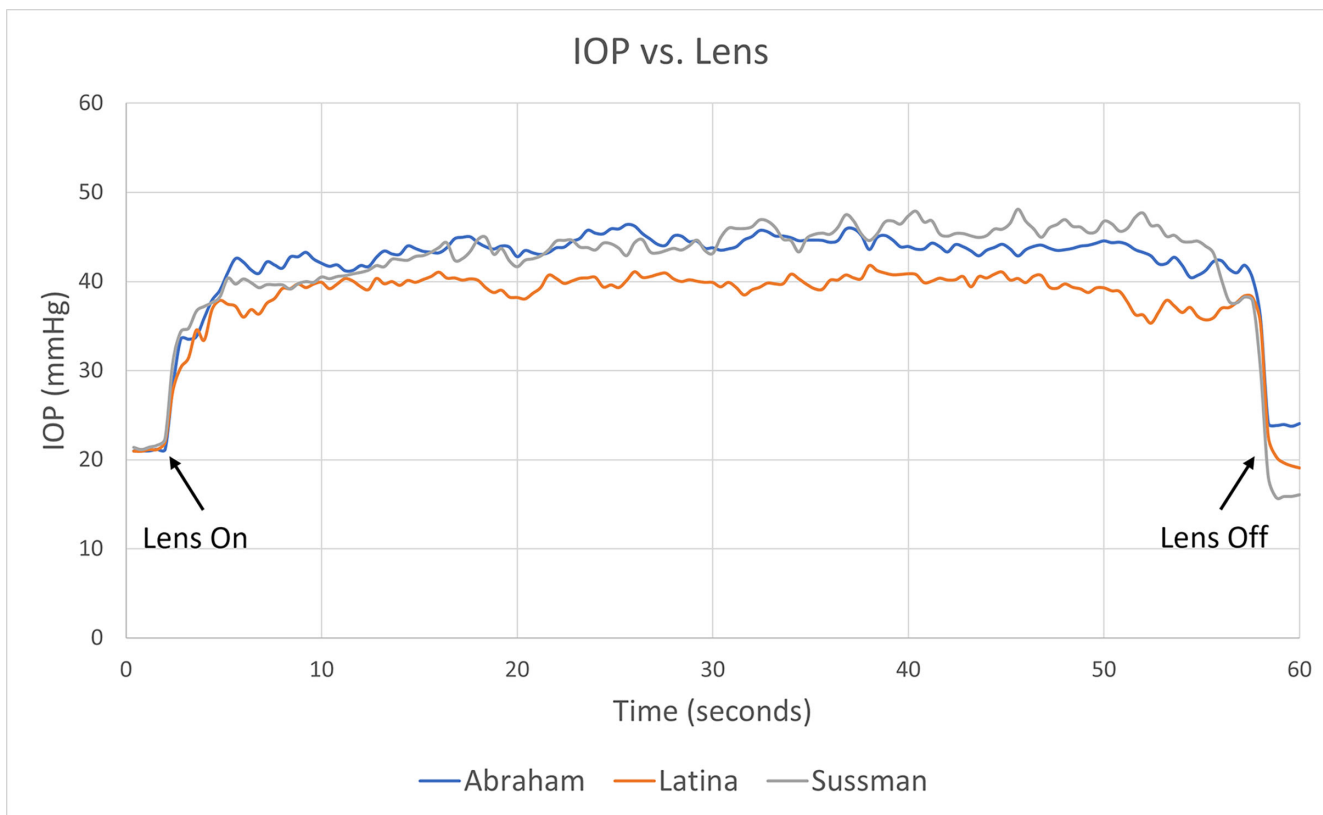


FIGURE 4. Average IOP over time for all measurements.

TABLE 2. Summary of IOP and Force Data for the Sussman, Latina, and Abraham Lenses as Well as the Special Cases of Indentation and Tamponade

	Sussman (n = 35)		Sussman Indentation (n = 10)		Latina SLT (n = 36)		Abraham (n = 36)		Abraham With Tamponade (n = 6)	
	Avg. Force (g)	Avg. IOP (mm Hg)	Avg. Force (g)	Avg. IOP (mm Hg)	Avg. Force (g)	Avg. IOP (mm Hg)	Avg. Force (g)	Avg. IOP (mm Hg)	Avg. Force (g)	Avg. IOP (mm Hg)
Average	40.3	43.2	92.8	80.5	66.7	39.8	65.5	42.7	189.3	82.3
Standard deviation	26.4	16.9	31.8	22.6	29.8	9.9	31.9	12.6	54.5	27.2
Minimum	9.7	22.8	43.0	45.4	16.0	22.9	15.0	26.3	143.0	63.3
Maximum	140.0	85.8	160.3	126.3	118.8	60.9	133.0	73.2	287.4	135.6

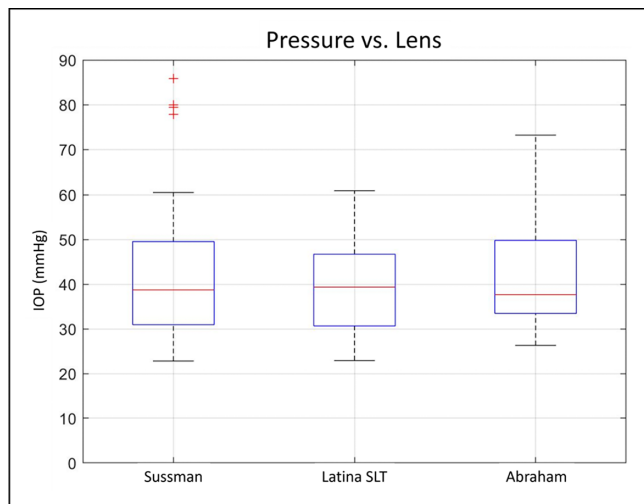


FIGURE 5. Boxplot showing the distribution of IOP among the Sussman, Latina, and Abraham lenses.

man lens was significantly lower than both the Latina lens ($P = 0.0008$) and the Abraham lens ($P = 0.001$). The box and whisker plot in Figure 7 shows the distribution of force on the eye between the three lenses. Figure 4 shows the average temporal response in the IOP during appplanation for all three lenses. There were no significant differences between dominant and non-dominant hands. Five ophthalmologists simulated indentation gonioscopy with the Sussman lens for a total of 10 measurements (each ophthalmologist performed the maneuver in 2 eyes). The average IOP and force on the eye during indentation gonioscopy with the Sussman lens were 80.5 ± 22.6 mm Hg and 92.8 ± 31.8 grams, respectively. The maximum recorded IOP was 126.3 mm Hg. Three ophthalmologists simulated tamponade during laser iridotomy with the Abraham lens for a total of six measurements (each ophthalmologist performed the maneuver in 2 eyes). The average IOP and force on the eye during tamponade with the Abraham lens were 82.2 ± 27.2 mm Hg and 189.3 ± 54.5 grams, respectively.

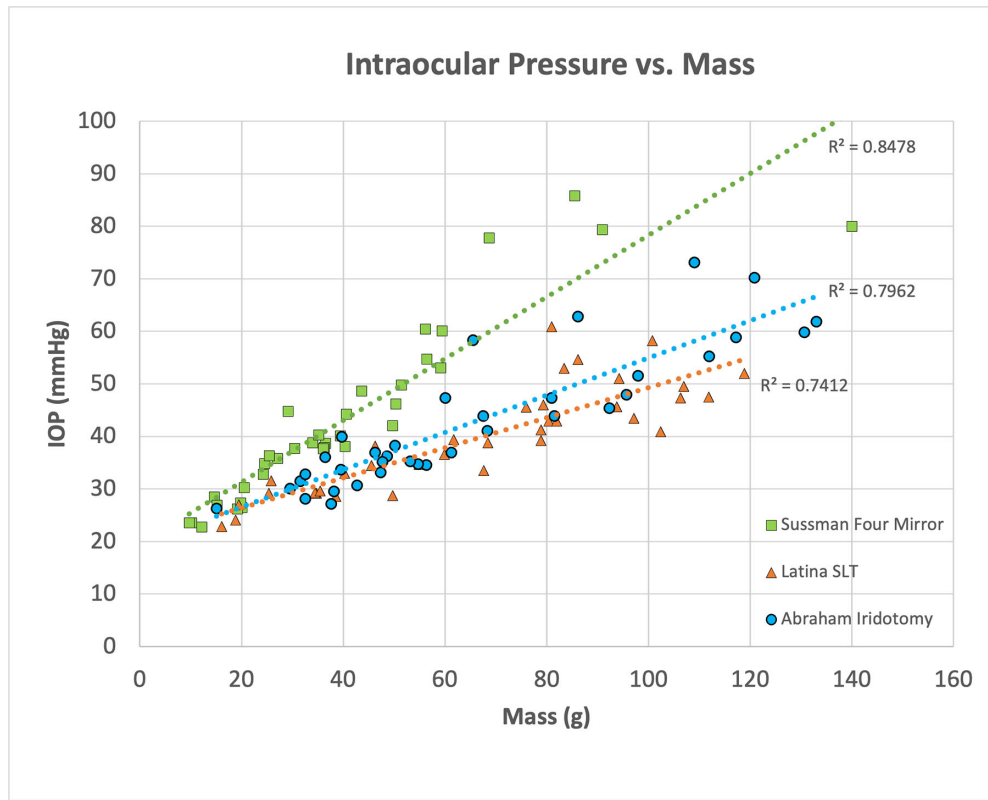


FIGURE 6. Graphic showing a correlation between force applied to the eye and IOP for each procedural lens.

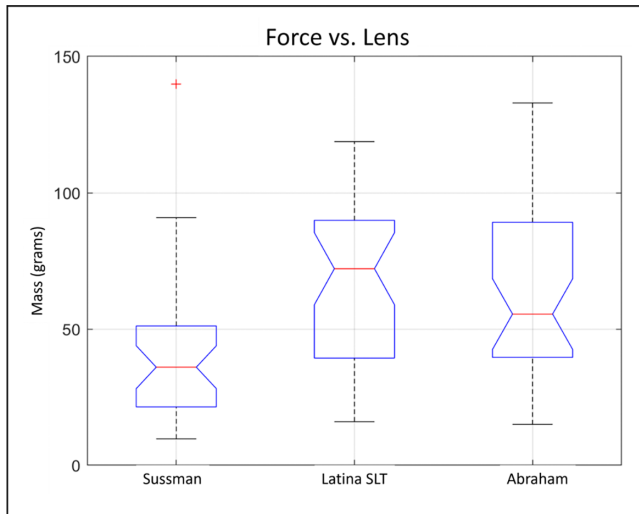


FIGURE 7. Boxplot showing the distribution of force on the eye among the Sussman, Latina, and Abraham lenses.

DISCUSSION

Overall, the mean IOP increase over baseline during simulated procedures for the 3 lenses and 6 ophthalmologists was roughly 20 mm Hg. This IOP rise correlated well with the duration of lens contact time and force onto the cornea. Instances of up to 65 mm Hg over baseline were recorded during indentation of the cornea with the lens, although this is typically over seconds. These findings are consistent with

the fact that the rigid interface of the lens is applanated upon a deformable but incompressible globe resulting in a force generated on the eye with a resultant increase in IOP. The amount and duration of IOP increase is variable and based on numerous factors, including examiner technique, different clinical scenarios where the lenses are used, anatomic variations, and differences in biomechanical properties of the globe. In a living eye, the return to baseline IOP may be variable based on age and outflow facility.

Considering that these transient IOP elevations occur in a sporadic frequency, lasting for a few seconds or minutes, and that the IOP returns to baseline shortly after the procedure, those events are unlikely to be harmful to the eye, including patients with glaucoma.⁹⁻¹² All three of these lenses are commonly and regularly used in glaucomatous eyes of varying severity. We are not aware of any reports of progression of disease or loss of vision from the impact of this transient IOP increase due to the lens. At least on a theoretical level and based on how common these procedures occur, as well as other common ocular interventions that cause transient IOP elevations, this level of acute IOP rise is unlikely to be harmful for this short time (minutes).^{9,10,12}

There are some theories behind the mechanism of glaucoma damage and how IOP plays an important role in the pathophysiology of the disease. It is known that persistent elevated IOP can induce irreversible retinal ganglion cell injury, and the duration of IOP insult is an important determinant of glaucoma damage, with chronic elevated IOP being the major risk factor for the development and progression of glaucoma.^{13,14} The severity of the glaucoma damage will depend on the degree of IOP elevation, duration/consistency of the insult and optic nerve susceptibil-

ity.^{9,15} Transient short isolated moderate IOP elevations are not felt to be a primary mechanism of glaucomatous damage. It is debatable what defines “moderate” IOP elevation and for what duration and frequency these elevations are risky.

There are several situations where a transient IOP elevation occurs, including diagnostic and surgical ophthalmic procedures, and this short-term IOP elevation appears to be well tolerated.^{16–18} For comparison, certain poses during the practice of yoga raise IOP by 17 to 29 mm Hg over baseline¹⁹ for a few minutes, while the common act of eye rubbing increases IOP 80 to 150 mm Hg over baseline for a few seconds.²⁰ During surgical procedures as phacoemulsification, IOP exceeds 60 mm Hg in up to 80% of the surgical time.²¹ Many patients with cataract have concomitant glaucoma; treating both conditions at once is common and appears safe, suggesting this transitory IOP elevation is well tolerated.²² Based on this, it is likely these transient isolated IOP elevations during these circumstances are not clinically significant. However, one may be more considerate of these in patients with very advanced glaucoma with elevated IOP.

On the other hand, extreme IOP elevation even for a short time may be problematic for some patients with glaucoma.¹⁵ Animal studies showed an IOP elevation as high as 90 mm Hg when creating a corneal flap for LASIK, and there were rare cases reported of hemi-retinal vein occlusion and visual field (VF) defects associated with LASIK.^{23–28} The last was more common in patients with pre-operatively ocular hypertension.^{26,27}

The results also indicated that the Sussman lens generated significantly less force on the eye while causing an IOP elevation no different from the Latina and Abraham lenses. This may be explained by the differences in contact diameter and radius of curvature of the lenses (see Table 1). The Sussman lens has the smallest contact diameter of the 3 lenses measuring 8.13 mm compared to 12.25 mm for the Latina and Abraham lenses. In addition, the Sussman lens has a larger radius of curvature than the Abraham and Latina lens. Furthermore, the Latina and Abraham lenses have flange whereas the Sussman does not. The large range of IOP rise during the three procedures is interesting to note, suggesting that differences in technique between ophthalmologists can have a significant effect on IOP elevation.

A limitation of the current study is that enucleated human eyes were used, and our results might not exactly mimic the behavior of living human eyes. There is no perfect model, and when choosing one to investigate the situation in living humans, it is important to consider the shortcomings of the model. The main difference between dead and living eyes is the lack of blood flow and pressure on the arterial and venous circulation. Previous studies showed differences in ocular rigidity before and after enucleation, which could influence how those eyes respond regarding IOP elevation.²⁹ Unfortunately, we are not able to do this experiment in living human eyes; however, attention has been given to ensure as much consistency as possible with the in vivo conditions of the eye, and we used the same methodology and model used in experiments to assess IOP elevation associated to surgical and laser procedures.^{30–32}

Another possible limitation is that the radius of curvature, diameter, and mechanical stiffness of the samples were not controlled and could have had a confounding effect on the measurements. For example, it is well known that the cornea becomes mechanically stiffer with age,³³ which can influence force measurements. Including eyes with a wider

range of ages in further studies would provide a more generalizable result.

CONCLUSIONS

Despite the minor limitations inherent in an ex vivo study, in cadaver eyes, standard procedural lenses elevate IOP, on average, by about 20 mm Hg above baseline. The findings from our experiment also highlight the importance of individual technique, as IOP can vary significantly between ophthalmologists, and even between successive measurements by a single ophthalmologist. There are several situations in ophthalmic diagnostics and treatment procedures where a transient IOP elevation occurs. Although this study does not address if this transitory IOP elevation could cause optic nerve damage, considering how universal these procedures are done and the apparent lack of long-term adverse effects after transitory IOP elevation, it likely does not pose a significant risk. However, more data are still necessary to better understand the impact of transient IOP elevations in healthy and glaucomatous eyes.

Acknowledgments

The authors thank Rick Lewis, John Berdahl, Ian Danford, Jack Li, and Melvin Sarayba for their participation in this study.

Supported by ViaLase who provided material support for this study.

An abstract of this paper was presented at Association for Research in Vision and Ophthalmology (ARVO) Meeting 2023.

Disclosure: **T. De Francesco**, Vialase (C); **E. Mikula**, Vialase (E); **W. Lummis**, Vialase (E); **N. Sangalang**, Vialase (E); **I.I.K. Ahmed**, Vialase (C)

References

- Heijl A, Leske MC, Bengtsson B, et al. Reduction of intraocular pressure and glaucoma progression: results from the Early Manifest Glaucoma Trial. *Arch Ophthalmol*. 2002;120:1268–1279.
- Weinreb RN, Aung T, Medeiros FA. The pathophysiology and treatment of glaucoma: a review. *JAMA*. 2014;311:1901–1911.
- Downs JC, Girkin CA. Lamina cribrosa in glaucoma. *Curr Opin Ophthalmol*. 2017;28:113–119.
- Sharma S, Tun TA, Baskaran M, et al. Effect of acute intraocular pressure elevation on the minimum rim width in normal, ocular hypertensive and glaucoma eyes. *Br J Ophthalmol*. 2018;102:131–135.
- Dubbelman M, Sicam VA, Van der Heijde GL. The shape of the anterior and posterior surface of the aging human cornea. *Vision Res* 2006; 46:993–1001.
- Thomas David Duane WT, Jaeger EA. *Duane's Ophthalmology*. Philadelphia, PA: Lippincott Williams & Wilkins; 2006.
- Dellaporta A. Historical notes on gonioscopy. *Surv Ophthalmol* 1975; 20:137–149.
- Bader J, Zeppieri M, Havens SJ. Tonometry [updated December 12, 2023]. In: *StatPearls [Internet]*. Treasure Island (FL): StatPearls Publishing; 2024. Available from: <https://www.ncbi.nlm.nih.gov/books/NBK493225/>.
- Balaratnasingam C, Morgan WH, Bass L, Cringle SJ, Yu DY. Time-dependent effects of elevated intraocular pressure on optic nerve head axonal transport and cytoskeleton proteins. *Invest Ophthalmol Vis Sci*. 2008;49(3):986–999.

10. Garhöfer G, Resch H, Weigert G, Lung S, Simader C, Schmetterer L. Short-term increase of intraocular pressure does not alter the response of retinal and optic nerve head blood flow to flicker stimulation. *Invest Ophthalmol Vis Sci*. 2005;46(5):1721–1725.
11. Chihara E, Honda Y. Analysis of orthograde fast axonal transport and nonaxonal transport along the optic pathway of albino rabbits during increased and decreased intraocular pressure. *Exp Eye Res*. 1981;32(2):229–239.
12. Lai JS, Tham CC, Chan JC, et al. Scanning laser polarimetry in patients with acute attack of primary angle closure. *Jpn J Ophthalmol*. 2003;47(6):543–547.
13. Quigley HA, Hohman RM, Addicks EM, Massof RW, Green WR. Morphologic changes in the lamina cribrosa correlated with neural loss in open-angle glaucoma. *Am J Ophthalmol*. 1983;95(5):673–691.
14. Burgoyne CF, Downs JC, Bellezza AJ, Suh JK, Hart RT. The optic nerve head as a biomechanical structure: a new paradigm for understanding the role of IOP-related stress and strain in the pathophysiology of glaucomatous optic nerve head damage. *Prog Retin Eye Res*. 2005;24(1):39–73.
15. Sharma S, Tun TA, Baskaran M, et al. Effect of acute intraocular pressure elevation on the minimum rim width in normal, ocular hypertensive and glaucoma eyes. *Br J Ophthalmol*. 2018;102(1):131–135.
16. Zhao Y, Li X, Tao A, Wang J, Lu F. Intraocular pressure and calculated diastolic ocular perfusion pressure during three simulated steps of phacoemulsification in vivo. *Invest Ophthalmol Vis Sci*. 2009;50(6):2927–2931.
17. Kerr NM, Abell RG, Vote BJ, Toh T. Intraocular pressure during femtosecond laser pretreatment of cataract. *J Cataract Refract Surg*. 2013;39(3):339–342.
18. Korenfeld MS, Dueker DK. Review of external ocular compression: clinical applications of the ocular pressure estimator. *Clin Ophthalmol*. 2016;10:343–357.
19. Jasien JV, Jonas JB, de Moraes CG, Ritch R. Intraocular pressure rise in subjects with and without glaucoma during four common yoga positions. *PLoS One* 2015;10:e0144505.
20. Turner DC, Girkin CA, Downs JC. The magnitude of intraocular pressure elevation associated with eye rubbing. *Ophthalmology* 2019;126:171–172.
21. Khng C, Packer M, Fine IH, Hoffman RS, Moreira FB. Intraocular pressure during phacoemulsification. *J Cataract Refract Surg* 2006;32:301–308.
22. Ling JD, Bell NP. Role of cataract surgery in the management of glaucoma. *Int Ophthalmol Clin* 2018;58:87–100.
23. Kasetsuwan N, Pangilinan RT, Moreira LL, et al. Real time intraocular pressure and lamellar corneal flap thickness in keratomileusis. *Cornea*. 2001;20(1):41–44.
24. Bissen-Miyajima H, Suzuki S, Ohashi Y, Minami K. Experimental observation of intraocular pressure changes during microkeratome suctioning in laser in situ keratomileusis. *J Cataract Refract Surg*. 2005;31(3):590–594.
25. Vetter JM, Holzer MP, Teping C, et al. Intraocular pressure during corneal flap preparation: comparison among four femtosecond lasers in porcine eyes. *J Refract Surg*. 2011;27(6):427–433.
26. Bushley DM, Parmley VC, Paglen P. Visual field defect associated with laser in situ keratomileusis. *Am J Ophthalmol*. 2000;129(5):668–671.
27. Weiss HS, Rubinfeld RS, Anderschat JF. LASIK-associated visual field loss in a glaucoma suspect. *Arch Ophthalmol*. 2001;119(5):774–775.
28. Smith BT, Park CH, Fekrat S. Hemi-retinal vein occlusion following LASIK. *Ann Ophthalmol (Skokie)*. 2006;38(2):139–140.
29. Ytteborg J. The role of intraocular blood volume in rigidity measurements on human eyes. *Acta Ophthalmol (Copenh)*. 1960;38:410–436.
30. Bolivar G, Garcia-Gonzalez M, Laucirika G, Villa-Collar C, Teus MA. Intraocular pressure rises during laser in situ keratomileusis: comparison of 3 femtosecond laser platforms. *J Cataract Refract Surg*. 2019;45(8):1172–1176.
31. Vetter JM, Faust M, Gericke A, Pfeiffer N, Weingärtner WE, Sekundo W. Intraocular pressure measurements during flap preparation using 2 femtosecond lasers and 1 microkeratome in human donor eyes. *J Cataract Refract Surg*. 2012;38(11):2011–2018.
32. Bradley JC, McCartney DL, Craenen GA. Continuous intraocular pressure recordings during lamellar microkeratotomy of enucleated human eyes. *J Cataract Refract Surg*. 2007;33(5):869–872.
33. Elsheikh A, Wang D, Brown M, Rama P, Campanelli M, Pye D. Assessment of corneal biomechanical properties and their variation with age. *Curr Eye Res* 2007;32:11–19.