tvst

Article

Bleb Analysis Using Anterior Segment Optical Coherence Tomography and Surgical Predictors of XEN Gel Stent

Yuri Kim[1], Su-Ho Lim[2], and Seungsoo Rho[1]

[1] Department of Ophthalmology, CHA Bundang Medical Center, CHA University, Seongnam, Republic of Korea
[2] Department of Ophthalmology, Daegu Veterans Health Service Medical Center, Daegu, Republic of Korea

Correspondence: Seungsoo Rho, Department of Ophthalmology, CHA Bundang Medical Center, CHA University, 59 Yatap-ro, Bundang-gu, Seongnam-si, Gyeonggi-do 13496, Republic of Korea.
e-mail: harryrho@gmail.com

Received: September 21, 2021
Accepted: January 24, 2022
Published: February 16, 2022

Keywords: XEN gel stent; intraocular pressure; glaucoma; pseudoexfoliation; anterior segment optical coherence tomography

Citation: Kim Y, Lim SH, Rho S. Bleb analysis using anterior segment optical coherence tomography and surgical predictors of XEN gel stent. Transl Vis Sci Technol. 2022;11(2):26, https://doi.org/10.1167/tvst.11.2.26

Purpose: To determine the early predictors of surgical success 6 months after XEN surgery among clinical parameters, including anterior segment optical coherence tomography (AS-OCT).

Methods: A total of 31 eyes with medically uncontrolled primary open-angle glaucoma or pseudoexfoliation glaucoma was enrolled retrospectively. Using AS-OCT, XEN tip location was categorized into intraconjunctival, intratenon, or uviform at day 1 and blebs were classified into no or low, high sparse, high thick, cystic, or mixed walls at month 6. Using slit-lamp photography, blebs were classified into no or low, localized avascular, diffuse avascular, localized vascular, or diffuse vascular blebs at month 6. Surgical success was defined as an intraocular pressure (IOP) of less than 14 mm Hg.

Results: Intraconjunctival and intratenon locations of the tip mostly created a high sparse wall, whereas the uviform type mostly created no or low wall and no or low bleb. The uviform type was linked to pseudoexfoliation glaucoma. A high sparse wall and diffuse avascular bleb showed a lower mean IOP than a high thick wall and localized vascular bleb. In the multivariate analysis, female sex and IOP at week 1 were early predictors of surgical success (8.45 times and 33.1% per 1 mm Hg-decrease, respectively).

Conclusions: Bleb evaluation using AS-OCT is valuable to correlate tip location and bleb morphology with clinical profiles, considering that a lower early postoperative IOP is linked to surgical success.

Translational Relevance: Bleb analysis using AS-OCT on day 1 could help to predict bleb morphology after 6 months, which is important to maintain the functioning bleb in the longer term.

Introduction

Minimally invasive glaucoma surgery (MIGS), as an umbrella term, represents a collection of conjunctival-sparing, ab interno procedures to control intraocular pressure (IOP) in glaucomatous eyes. The recommendation of traditional incisional filtration surgeries (e.g., trabeculectomy or implantation of a glaucoma drainage device) to patients with early to moderate disease is a challenge, considering their high postoperative complication rates.[1] Hence, the rapid adoption of MIGS procedures in the United States from 2013 to 2018 with a subsequent decline of traditional glaucoma surgery use indicates that clinical evidence of safety and effectiveness is becoming more important than ever.[2]

Among a large number of MIGS procedures currently available in the market, the XEN gel stent (Allergan, Dublin, CA) is a subconjunctival drainage type and bleb-forming MIGS, which has similar efficacy and safety profiles compared with trabeculectomy.[3] The ab interno technique using the XEN gel stent enables to have less surgical trauma and fewer time-consuming steps resulting in lower rates of postoperative complications (e.g., hyphema, wound leak). Theoretically, less manipulation of the conjunctiva could prevent subconjunctival bleeding, which is a trigger to fibroblast activation, and facilitate greater

Copyright 2022 The Authors

This work is licensed under a Creative Commons Attribution-NonCommercial-NoDerivatives 4.0 International License.

Downloaded from hwmaint.iovs.org on 04/23/2024

physiological absorption of the aqueous humor via more preserved conjunctival lymphatics.[4]

Bleb evaluation after filtration surgery has been considered as a crucial step for the assessment of clinical predictors of surgical success. The bleb grading systems traditionally used for trabeculectomy via slit-lamp examination need to be set up newly for the XEN procedure because the vascularity, reflectivity, and height of the successful blebs in both surgeries are known to be different.[5,6] In addition, anterior segment optical coherence tomography (AS-OCT) offers advantages over the slit-lamp evaluation to accurately measure the bleb parameters and to scrutinize the internal structures of the bleb.

Thus, in this study, we aimed to determine the predictors of surgical success after a XEN implantation procedure in clinical parameters and bleb morphology by characterizing these blebs using AS-OCT and slit-lamp photographs.

Methods

In this retrospective chart review, the electronic medical records of all patients who underwent XEN gel stent surgery for medically uncontrolled primary open-angle glaucoma or PXG (according to the approval of the relevant health authorities in South Korea) at CHA Bundang Medical Center between November 2018 and June 2019 were reviewed and consecutively enrolled. PXG was diagnosed by slit-lamp visualization of characteristic fibrillar pseudoexfoliative material on the lens or at the pupil margin. All participants had no history of previous glaucoma surgery. The study was approved by the Institutional Review Board of CHA Bundang Medical Center and was conducted at the CHA Glaucoma Clinic of CHA Bundang Medical Center in accordance with the tenets of the Declaration of Helsinki. Written informed consent was obtained from all patients without the waiver. The main goal of this study was to identify the risk factors as early as possible that can affect bleb morphology and the surgical outcome of XEN implantation after 6 months.

Surgical Success Definitions

Success was defined as attaining an IOP of less than 14 mm Hg and a more than 20% reduction of preoperative IOP, with no additional glaucoma surgery or findings of vision-threatening complications (qualified success, with or without any ocular hypotensive medications; complete success, without any ocular hypotensive medications). Needling was not considered as glaucoma surgery. Hypotony was defined as having an IOP of less than 6 mm Hg at any visit.

Surgical Procedure

All surgical procedures were performed by a skilled surgeon (S.R.) after informed consent was obtained from all patients. After topical anesthesia, the eye was prepared for the operation. We mixed 0.05 mLof 2% lidocaine with epinephrine (1:10000, 0.1 mL) was injected using a 30G needle into the superior subconjunctival space located approximately 6 mm apart from the region that the XEN tip is going to be occupied. After an injection of viscoelastics to maintain the anterior chamber via a 1-mm side port, the XEN injector was advanced through a 1.5-mm clear corneal incision toward the opposite superonasal target angle. A XEN implant was then inserted through this angle into the subconjunctival space 2 mm apart from the limbus. After confirming the allocation of XEN in the subconjunctival area, the injector was moved backward and removed gently out of the corneal incision. The proper location and length (approximately 1 mm) of XEN in the angle were checked using a surgical gonioscope, and the mobility and length (approximately 3 mm) of the subconjunctivally located part of the XEN were confirmed. Irrigation and aspiration was done to remove the viscoelastics. The corneal wounds were secured by hydrosealing using a balanced salt solution. 0.05 mL of mitomycin C (MMC) 0.4 mg/mL or 0.2 mg/mL (they were unintentionally determined owing to a national shortage of MMC supply for a couple of months in early 2019) was injected into the superonasal subconjunctival space using a 30G needle.

Postoperative Management

The postoperative medication included topical corticosteroid and antibiotic use four times a day for 1 month, followed by tapered down over 3 to 6 months. During the whole follow-up, needling treatment with or without 5-fluorouracil on the bleb was performed at the slit-lamp when the treatment target IOP was not achieved in at least one visit after 1 month postoperatively. YAG fibrinolysis was planned to be performed to relieve the obstruction of the XEN tip in the anterior chamber if it is noted. Glaucoma medications were reintroduced, considering each patient's tolerated eye drops after sufficient interviews. However, a revision surgery was performed, such as an alternative filtering surgery, in refractory cases.

Downloaded from hwmaint.iovs.org on 04/23/2024

Assessment of Bleb Morphology Using AS-OCT

Postoperative blebs were imaged using a Spectralis OCT (Heidelberg Engineering GmbH, Heidelberg, Germany) on postoperative day 1, week 1, week 2, and months 1, 2, 3, and 6, as described elsewhere.[7,8] Briefly, a total of 41 section scans were aligned along with the parallel line at the point where the XEN tip was located. Images with quality scores of higher than 25 were included in the final qualitative analysis. The maximum bleb height was selected and measured within the 41 sections that were obtained at each visit.

Statistical Analysis

Patient demographics were compared using the χ^2 test with the Fisher exact test for categorical variables and Mann–Whitney *U* tests for continuous variables. Owing to the small sample size of each group, nonparametric tests using a Kruskal–Wallis analysis were performed to compare the means of three or more independent groups. Bonferroni error corrections were applied to control for inflated type I errors.[9] Kappa values were extracted to evaluate the agreement of AS-OCT and slit-lamp photo classifications. The Kappa statistic was calculated from a 2 × 2 table. The interpretation of Kappa value was made according to Cohen's description.[10] Multivariate logistic regression tests were used to calculate odds ratios. All analyses were performed using PASW software (version 18.0; SPSS, Inc., Chicago, IL). Statistical significance was set differently at a *P* value of less than 0.0167 and a *P* value of less than 0.0050 for the post hoc analyses only that were performed in three groups and five groups, respectively (except at a *P* value of less than 0.05 for all other analyses).

Results

Demographics of Success and Failure Groups

A standard ab interno XEN implantation (described in the Methods section) was performed in 31 eyes of 31 patients who were followed for at least 6 months. According to the definition of success, as described in the Methods section, the demographic features of the success and failure groups are summarized in Table 1. No significant differences

Table 1. Comparison of Demographic Features According to the Definitions of Success

	Qualified Success			Complete Success		
	No (*n* = 18)	Yes (*n* = 13)	*P* Value	No (*n* = 19)	Yes (*n* = 12)	*P* Value
Age	65.61 ± 14.85	68.31 ± 16.19	0.561	66.58 ± 15.03	67.00 ± 16.16	0.919
Sex (female, %)	22.2	69.2	0.013*	26.3	66.7	0.060
Axial length (mm)	24.78 ± 1.81	25.37 ± 2.70	0.704	24.71 ± 1.78	25.53 ± 2.76	0.429
CCT (μm)	519.4 ± 32.9	523.5 ± 25.6	0.509	518.5 ± 32.3	525.3 ± 25.8	0.301
Preoperative VFI (%)	48.6 ± 34.5	51.5 ± 30.7	0.932	47.3 ± 34.0	53.9 ± 31.0	0.682
Preoperative IOP (mm Hg)	29.6 ± 9.8	28.9 ± 10.9	0.936	29.4 ± 9.6	29.2 ± 11.3	0.903
0.04% MMC (%)	33.3	69.2	0.073	36.8	66.7	0.149
Preoperative medications (*n*)	3.28 ± 1.13	2.85 ± 1.21	0.332	3.21 ± 1.13	2.92 ± 1.24	0.547
Pseudophakia (%)	61.1	69.2	0.718	63.2	66.7	1.000
Hypotony (%)	66.7	76.9	0.696	63.2	83.3	0.418
Needling (%)	72.2	15.4	0.003*	68.4	16.7	0.009*
Choroidal detachment (%)	11.1	8.3	1.000	10.5	9.1	1.000
A/C reformation (%)	61.1	38.5	0.285	57.9	41.7	0.473
POAG (%)	66.6	69.2	1.000	68.4	66.6	1.000
PXG (%)	33.3	30.8	1.000	31.6	33.3	1.000
Tip locations			0.633			0.940
Subconjuntival	66.7%	33.3%		66.7%	33.3%	
Intratenon	61.1%	38.9%		61.1%	38.9%	
Uviform	42.9%	57.1%		57.1%	42.9%	

A/C, anterior chamber; POAG, primary open-angle glaucoma.
Values are presented as mean ± standard deviation unless otherwise indicated.
*$P < .05$.

Downloaded from hwmaint.iovs.org on 04/23/2024

Table 2. Comparison of IOP (mm Hg) and Maximal Bleb Heights (µm) Over Time

	Qualified Success			Complete Success		
	No	Yes	*P* Value	No	Yes	*P* Value
IOP						
Preoperative	29.61 ± 9.80	28.92 ± 10.89	0.936	29.42 ± 9.56	29.17 ± 11.34	0.903
Day 1	5.61 ± 2.30	4.77 ± 1.92	0.289	5.84 ± 2.46	4.33 ± 1.16	0.098
Day 2	5.61 ± 2.91	4.92 ± 2.22	0.503	5.79 ± 2.94	4.58 ± 1.93	0.242
Week 1	9.17 ± 4.09	6.69 ± 2.18	0.032*	9.16 ± 3.98	6.50 ± 2.15	0.017*
Week 2	10.11 ± 2.93	9.62 ± 3.73	0.492	10.11 ± 2.85	9.58 ± 3.90	0.513
Month 1	14.67 ± 5.63	9.54 ± 4.08	0.002*	14.47 ± 5.53	9.42 ± 4.23	0.002*
Month 2	16.11 ± 8.09	10.25 ± 1.66	0.002*	16.11 ± 8.09	10.25 ± 1.66	0.002*
Month 3	15.44 ± 4.93	10.69 ± 2.02	0.002*	15.05 ± 5.08	10.92 ± 1.93	0.009*
Month 6	16.29 ± 3.10	11.15 ± 1.86	<0.001*	15.83 ± 3.59	11.42 ± 1.68	<0.001*
Max bleb Ht						
Day 1	981.1 ± 389.8	884.5 ± 327.2	0.540	981.2 ± 378.9	876.3 ± 430.3	0.459
Week 1	1056.3 ± 342.6	1037.4 ± 500.9	0.465	1106.0 ± 397.2	957.2 ± 427.2	0.177
Week 2	1176.2 ± 447.6	977.4 ± 500.0	0.226	1219.5 ± 474.3	892.2 ± 412.0	0.071
Month 1	1306.8 ± 439.5	1120.1 ± 465.6	0.226	1343.3 ± 455.7	1046.8 ± 400.3	0.064
Month 2	1406.0 ± 473.2	1173.1 ± 404.7	0.125	1437.3 ± 479.7	1104.2 ± 333.6	0.035*
Month 3	1383.0 ± 475.4	1262.9 ± 454.0	0.341	1417.3 ± 483.6	1201.5 ± 413.9	0.134
Month 6	1342.8 ± 473.7	1281.3 ± 532.6	0.767	1381.5 ± 485.6	1215.9 ± 505.7	0.378

Max Bleb Ht, maximal bleb height.
Values are presented as mean ± standard deviation unless otherwise indicated.
* $P < 0.05$.

were noted between the two groups according to the definitions regarding age, axial length, central corneal thickness, preoperative visual field index, preoperative IOP, the proportion of 0.04% MMC use, number of preoperative medications, the proportion of pseudophakia, postoperative hypotony rate, choroidal detachment, anterior chamber reformation rate, and subtypes of glaucoma (primary open-angle glaucoma; or pseudoexfoliation glaucoma [PXG]), except sex and needling rate. Nine of the 13 (69.2%) qualified success group were female ($P = 0.013$). Needling rates were significantly lower in the qualified and complete success groups than in both failure groups ($P = 0.003$ and $P = 0.009$, respectively). Although the higher MMC concentration group (0.04%) showed higher success rates than the lower MMC concentration group (0.02%), this difference did not attain statistical significance.

Longitudinal Measurements of Factors

At each visit, the IOPs of the success and failure groups were compared (Table 2). The mean IOP of each group showed a statistical significance at postoperative week 1 according to both success definitions (qualified and complete; $P = 0.032$ and $P = 0.017$, respectively). The gap narrowed at week 2; however, it widened again after postoperative month 1 and regained statistical significance.

The maximal bleb height at 2 months in the complete success group was significantly lower than that in the complete failure group ($P = 0.035$, Table 2). Otherwise, there were no differences at any other visit.

The numbers of medications preoperatively and at postoperative months 1, 2, 3, and 6 were fewer in the qualified and complete success groups than in both failure groups, but it did not reach statistical significance ($P > 0.05$) (Figs. 1A and 1B). The endothelial cell count (ECC) at each visit was not different between the success and failure groups according to the definitions of qualified success and complete success ($P > 0.05$, Figs. 1C and 1D). One eye had a trabeculectomy at postoperative month 2 owing to bleb failure and was, therefore, determined as a failure.

Bleb Classifications

The tip location of XEN was categorized into three groups according to their relative location to the interface between the conjunctiva and Tenon's fascia (CTI)

translational vision science & technology

Downloaded from hwmaint.iovs.org on 04/23/2024

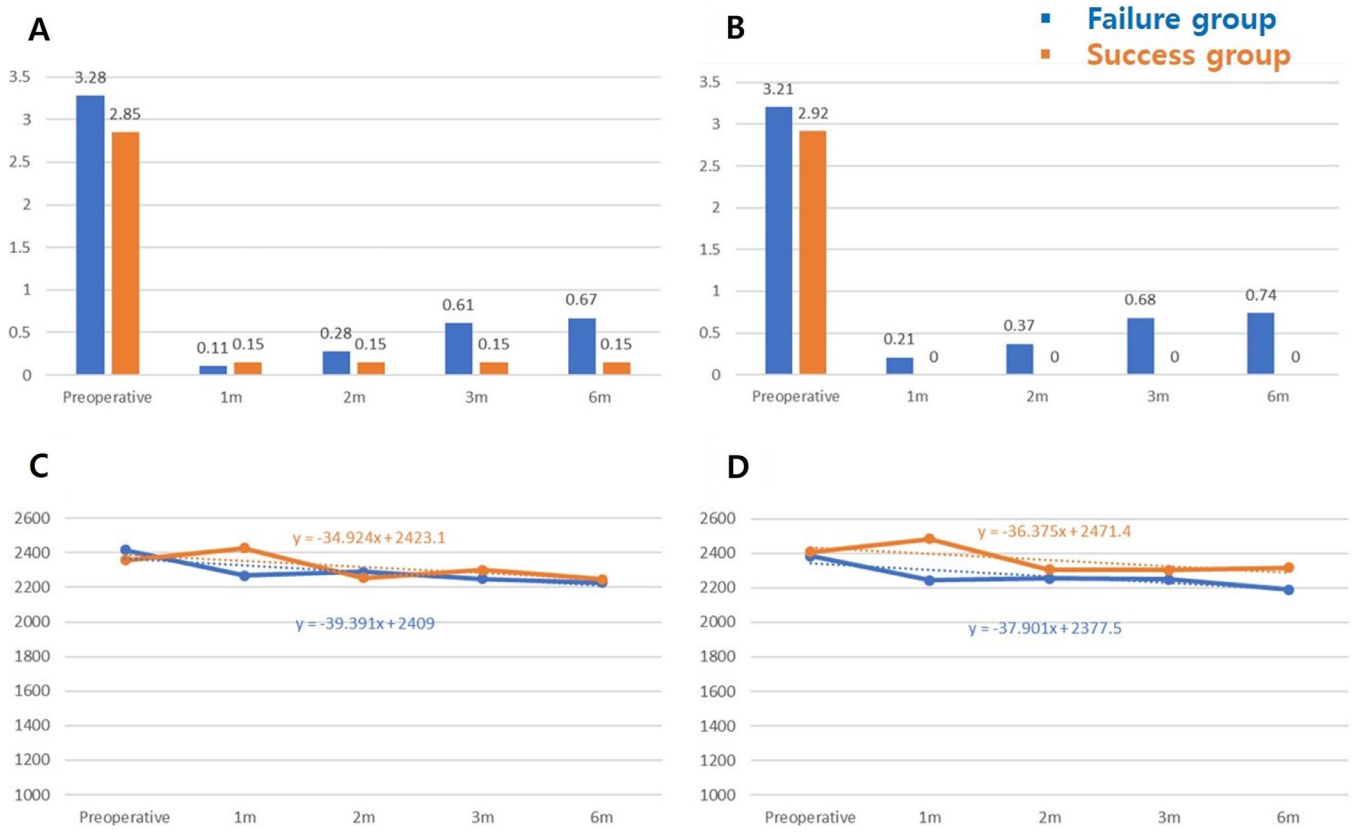

Figure 1. Number of medications and change in the ECC over time. (**A**, **B**) Number of medications according to the definitions of qualified (**A**) and complete successes (**B**). (**C**, **D**) ECC was not different between the failure and the success groups according to the definitions of qualified (**C**) and complete successes (**D**).

on postoperative day 1 (Fig. 2). They would fall into intraconjunctival and intratenon types if the tip is located above the CTI and underneath the CTI, respectively. If the relative location of the tip is not clear or the CTI is not visible (Fig. 2D), they would always seem to fall into uviform type, given their numerous protuberances (or bumps) underlying the inner bleb wall. The uviform type bleb was highly linked to PXG ($P = 0.022$). The difference in surgical success rates was not statistically significant among the three groups (Table 1). The mean maximal IOP during the first 6 months was lowest in the intratenon group compared with the intraconjunctival and uviform groups, although it did not reach the statistical significance (14.78 ± 3.87, 20.50 ± 12.76, and 19.71 ± 7.93 mm Hg, respectively; $P = 0.393$).

Bleb morphology in AS-OCT was classified into five groups (no or low wall, high sparse wall, high thick wall, cystic wall, and mixed wall) as described in Figure 3, and bleb morphology in slit-lamp photographs was classified into five groups (no or low bleb, localized avascular bleb, diffuse avascular bleb, localized vascular bleb, and diffuse vascular bleb) as described in Figure 4. Bleb distribution at postoperative 6 months according to the tip location on day 1 is depicted in Figures 5A and 5B. The majority of intraconjunctival and intratenon types became high sparse wall (4/6 and 9/18, respectively) and avascular bleb (2/6 and 8/18, respectively) after 6 months, whereas the uviform type mostly became no or low wall (4/7) and no or low bleb (4/7). Nonuviform types (intraconjunctival and intratenon) were linked to high sparse wall with statistical significance ($P = 0.037$) but not linked to an avascular bleb ($P = 0.372$). The uviform type was linked to no or low wall and no or low bleb with statistical significance ($P = 0.014$ and 0.005, respectively). The high sparse wall in AS-OCT classification and avascular blebs (localized and diffuse) in slit-lamp photo classification showed substantial agreement according to the Cohen's kappa result (Kappa = 0.741; $P < 0.001$).

The post hoc comparison of the mean IOPs according to the bleb classifications in AS-OCT and slit-lamp images revealed statistical significance (Fig. 6A and 6B). A high sparse wall showed a lower mean IOP compared with a high thick wall ($P < 0.001$).

translational vision science & technology

Downloaded from hwmaint.iovs.org on 04/23/2024

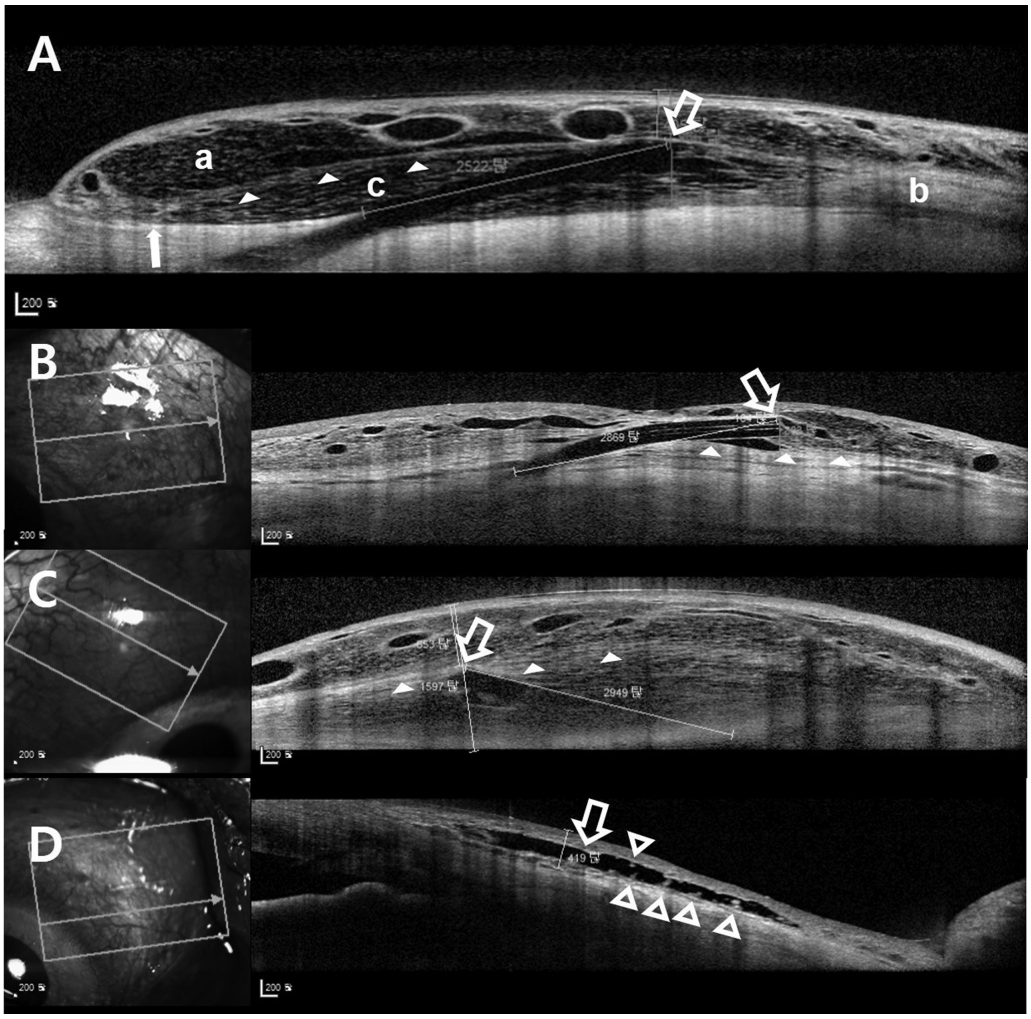

Figure 2. Tip location of XEN on day 1. The tip location was classified into three groups. Note that the tip of XEN and the interface between the conjunctiva and Tenon's capsule are indicated with hollow arrows and arrowheads, respectively. (**A**) Anterior segment optical tomography image of a bleb after XEN gel stent. (a) Hydrated conjunctiva. (b) Tenon's capsule. (c) Hydrated Tenon's capsule. (**B**–**D**) The tip location is classified into three groups. (**B**) Intraconjuncitval location. (**C**) Intratenon location. Note that the tip stays over the interface. (**D**) Uviform location. Note that there are numerous protuberances (*hollow arrowheads*) covering the inner bleb wall in uviform type, which is highly linked to PXG. It was not possible to determine whether the tip is located in the intraconjunctival space or intratenon space when it is defined as uviform type owing to its less hydrated structure.

A diffuse avascular bleb showed a lower mean IOP compared with a localized vascular bleb ($P = 0.003$). A localized avascular bleb showed a relatively lower mean IOP compared with localized vascular and diffuse vascular blebs, although they did not reach the statistical significance ($P = 0.006$ and 0.012, respectively, according to the Bonferroni correction). A diffuse avascular bleb showed a relatively lower mean IOP compared with a diffuse vascular bleb, although it did not reach statistical significance ($P = 0.026$, according to the Bonferroni correction). There was no statistical significance among other multiple comparisons.

Multivariate Logistic Regression Analysis

Including certain variables that were statistically significant in univariate analyses, such as female sex and IOP at postoperative week 1, a glaucoma subtype (PXG) was added to the multivariate logistic regression analysis based on previous studies.[11,12] Meanwhile, the maximal bleb height and needling rates were excluded in the multivariate analysis because the purpose of this study was to figure out the predictors of surgical success as swift as possible, although they were statistically significant at postoperative month 2 and during the first 6 months, respectively. The adjusted R^2 values

translational vision science & technology

Downloaded from hwmaint.iovs.org on 04/23/2024

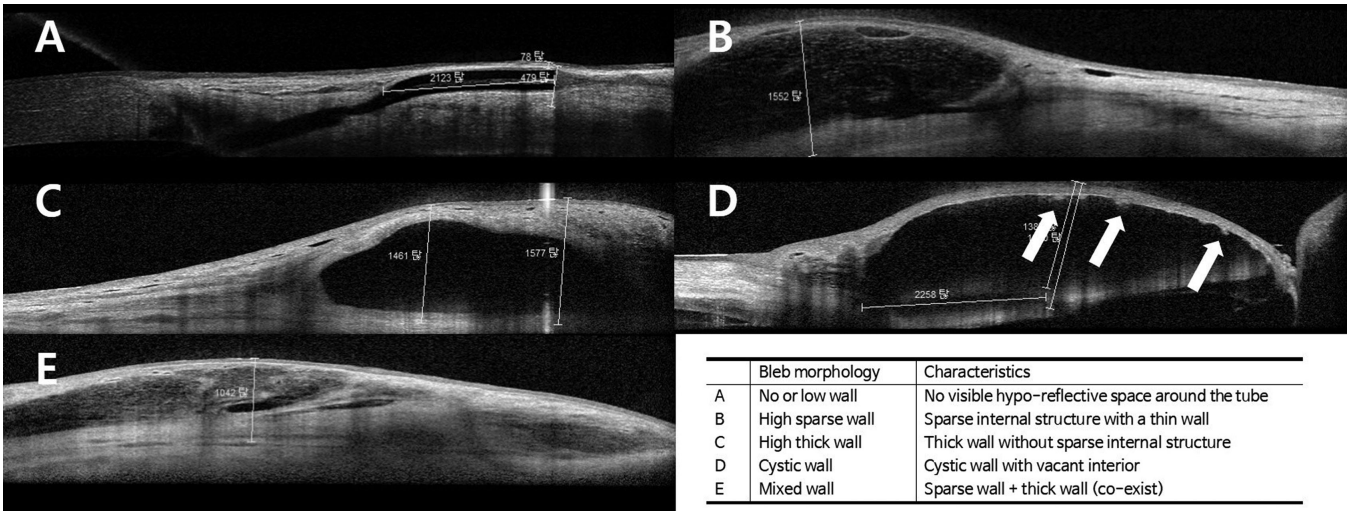

	Bleb morphology	Characteristics
A	No or low wall	No visible hypo-reflective space around the tube
B	High sparse wall	Sparse internal structure with a thin wall
C	High thick wall	Thick wall without sparse internal structure
D	Cystic wall	Cystic wall with vacant interior
E	Mixed wall	Sparse wall + thick wall (co-exist)

Figure 3. Bleb classification via AS-OCT imaging at 6 months postoperatively. Bleb morphology in AS-OCT is classified into five groups as described elsewhere in this article. Note that the protuberances (*white arrows*) covering the inner bleb wall in the cystic type, which was a uviform type on day 1 (C in Fig. 2), is often maintained even after 6 months postoperatively.

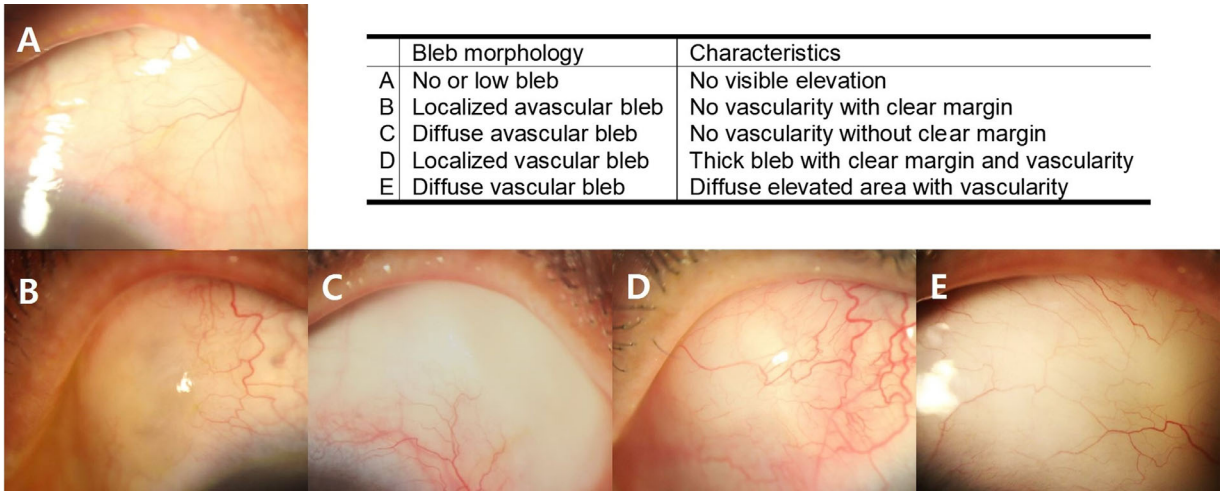

	Bleb morphology	Characteristics
A	No or low bleb	No visible elevation
B	Localized avascular bleb	No vascularity with clear margin
C	Diffuse avascular bleb	No vascularity without clear margin
D	Localized vascular bleb	Thick bleb with clear margin and vascularity
E	Diffuse vascular bleb	Diffuse elevated area with vascularity

Figure 4. Bleb classification via slit-lamp photography at 6 months postoperatively. Bleb morphology via slit-lamp photography is classified into five groups as described elsewhere in this article.

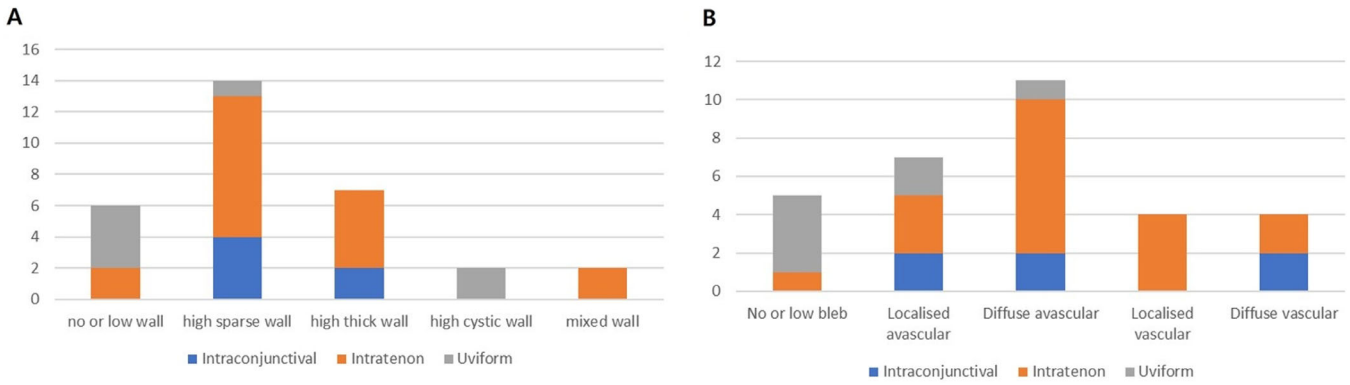

Figure 5. Bleb distribution according to tip location. (**A, B**) Bleb distribution according to tip location. (**A**) One-half of the intraconjunctival and intratenon types become high sparse wall, whereas the majority of uviform type become no or low wall. (**B**) Most intraconjunctival and intratenon types create avascular blebs (localized or diffuse), whereas uviform type mostly becomes no or low bleb.

Downloaded from hwmaint.iovs.org on 04/23/2024

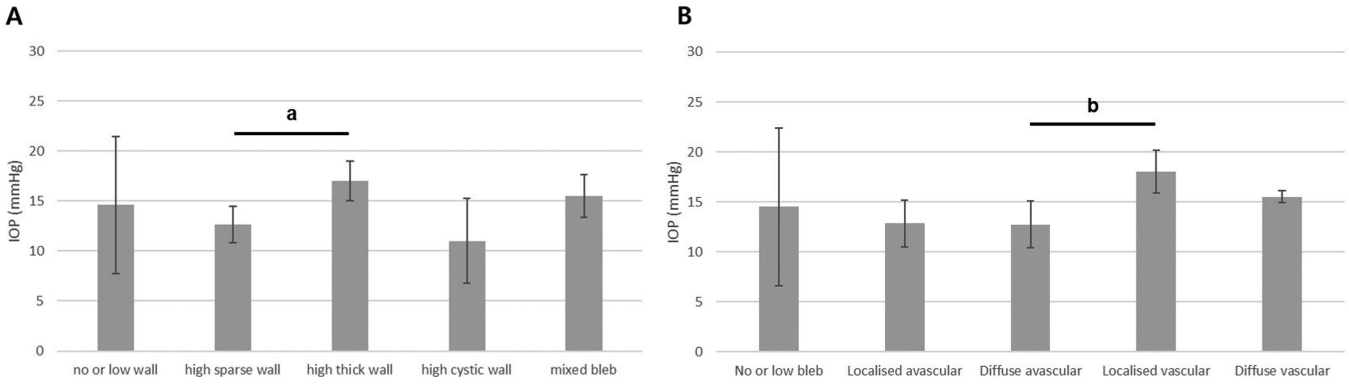

Figure 6. Mean IOP according to bleb classifications. (**A, B**) Comparison of IOP at 6 months. (**A**) Comparison of IOP according to OCT classification. High sparse wall shows lower mean IOP compared with high thick wall (Kruskal Wallis test; $P = 0.014$). (**B**) Comparison of IOP according to slit-lamp classification. Diffuse avascular show lower mean IOP compared with localized vascular (Kruskal Wallis test; $P = 0.030$). A post hoc analysis reveals the groups that are significantly different (a, $P < 0.001$; b, $P = 0.003$).

Table 3. Logistic Regression Analysis for Surgical Success (Multivariate)

	Qualified Success			Complete Success		
	OR	*P* Value	95% CI	OR	*P* Value	95% CI
Sex (female)	8.450	0.020*	1.390–51.391	5.485	0.058	0.945–31.829
PXG	1.194	0.861	0.165–8.649	1.809	0.556	0.252–12.998
IOP at 1 week (mm Hg)	0.710	0.078	0.485–1.039	0.669	0.049*	0.448–0.998

CI, confidence interval; OR, odds ratio.

Adjusted R^2 (significance of the model, $P < 0.05$) = 0.306 and 0.286 (enter method; for qualified success and complete success, respectively).

*$P < 0.05$.

(significance of the model, $P < 0.05$) were compared with determine the variables of best fit for the model. The variation inflation factors in the model were all less than 2, which implies low multicollinearity. Table 3 shows that the probability of a qualified success rate increased by 8.450 times if the patient was female ($P = 0.020$) and the probability of complete success rate decreased by 33.1% when the IOP at 1 week increased by 1 mm Hg ($P = 0.049$).

Discussion

This study assessed the early surgical factors of successful XEN implantation regarding the relationship between IOP control and bleb morphology. The XEN gel stent is a relatively new device in glaucoma surgery, showing promising efficacy data over the last decade. Because of the academic background of its physical structure, which is 6 mm long and has a 45 µm-lumen size, there is a major difference in the blebs created by this device in the initiation spot amid the conjunctival geographics compared with blebs created by trabeculectomy. This difference makes the XEN bleb start more posteriorly at the beginning and, therefore, shapes them flatter, which is possibly affected by eyelid movement. According to previous studies, XEN blebs were found to be significantly flatter than trabeculectomy blebs.[6,13] Our data also showed that the maximal bleb height in the success group was significantly lower than that in the failure group at postoperative month 2, which can be additionally explained by the relative outflow restriction of the XEN that limits the outflow pressure into the subconjunctival space. However, the XEN bleb is expected to follow the characteristics of a filtering bleb which has a high correlation between the IOP-lowering efficacy and bleb characteristics (e.g., size, vascularity). It is reasonable to say that the XEN bleb is also likely to fail if the bleb shows less of an internal capacity to manage the aqueous humor outflow.

In our study, the correlation of the MMC concentration to success rates (0.02% vs. 0.04%) was not statistically significant, although the 0.04% group showed higher success rates than the 0.02% group. Jampel[14] described that the viability of a human Tenon's capsule fibroblast was not affected by the exposure time of

Downloaded from hwmaint.iovs.org on 04/23/2024

MMC. Seol et al.[15] reported that the MMC concentration did not influence the characteristics of the trabeculectomy bleb such as vascularity and bleb height. Still, there is a suggestion that a higher MMC dose may lead to higher success rates; however, the heterogeneity of the study's design makes it difficult to confirm based on the current evidence, and additional researches are needed to clarify this. We reported that the early hypotony rate that might be linked to MMC exposure was 60% to 70%, which was higher than that reported in previous studies. Hypotony in the early postoperative period after the XEN procedure is relatively common, which seems to happen owing to peritubular flow created by the difference between the diameter of XEN and the lumen diameter of the injector needle containing XEN gel stent. In addition, the higher rate of early hypotony in our study can be further elucidated by the ethnic difference in the scleral elasticity between Korean and Caucasian populations, as reported by Park et al.[16]

The goal of our study was to determine the early predictors of surgical success. In that regard, we found that IOP at postoperative week 1 could be a good predictive value, which was consistent with the findings of Cutolo et al.,[17] determining that an IOP of more than 9 mm Hg on postoperative day 1 was a strong predictor of surgical failure after XEN. Similarly, Okimoto et al.[11] reported that an IOP of less than 8 mm Hg at postoperative week 2 was linked to a high probability of surgical success after filtering surgery. In our additional analysis, we also found that an IOP of less than 7.5 mm Hg at postoperative week 1 was significantly linked to higher qualified and complete success rates, although the area under the curve was small. These results raised the issue of the possible need for early needling after XEN, in contrast with conventional trabeculectomy, which allows more early postoperative options for IOP management (e.g., releasable suture technique, laser suture lysis) than XEN. Needless to say, the intraoperative mobility check of the XEN tip should be guaranteed before discussing this issue on surgical failure.

In our study, the tip location was not related to surgical success, which was defined as IOP of less than 14 mm Hg (complete success: 33.3%, 38.9%, and 42.9% in the subconjunctival, intratenon, and uviform groups, respectively). However, it is intriguing that the success rates in the intraconjunctival and intratenon groups were relatively higher if the complete success criteria were defined as an IOP of less than 18 mm Hg (data not shown; 83.3%, 66.7%, and 42.9%, respectively). This metric may imply that the IOP of the intraconjunctival and intratenon group could be controlled within the mid-teen level, whereas that of the uviform group may widely vary. Lenzhofer et al.[18] reported that the intratenon or subtenon location of the XEN tip determined by AS-OCT images was related to surgical success. A uniform bleb in the early postoperative period and microcystic multiform bleb at postoperative month 3 according to their classification, which were similar to no or low wall and high cystic wall by our classification, respectively, seemed to be predictive of greater surgical failure at postoperative month 12. As with their report, in our post hoc analysis, we also found that the intraconjunctival and intratenon type classified by the tip location on day 1 became high sparse wall (AS-OCT) or avascular blebs (slit-lamp image), which were more linked to lower mean IOP at month 6 postoperatively, than the other types, such as high thick wall or vascular blebs. So, the proper XEN tip location may be the precondition of a successful XEN bleb.

Because the AS-OCT imaging technique enables us to distinguish Tenon's fascia from the conjunctival stroma, the XEN tip location can be determined. In our current perspective, Spectralis OCT is one of the most useful OCT tools to evaluate the filtering blebs in terms of image acquisition and resolution next to Visante OCT (Carl Zeiss Meditec AG, Germany) that used by Lenzhofer et al. Although we cannot directly compare our AS-OCT classification with that of Lenzhofer et al. in terms of different devices and settings, we agree with their opinion that a deeper XEN implant position in the conjunctiva could be more beneficial for IOP control, given that the mean maximal IOP of the intratenon group during the first 6 months was lowest among the three groups from our data.

Needling is one of the frequently performed procedures after filtering surgery, which can affect bleb appearance. The need for this procedure is a limitation of our study, similar to many bleb-related observational studies. Therefore, we considered the needling procedure as a natural course of bleb management, so that all the variables were analyzed to determine the factors affecting successful bleb formation at month 6 postoperatively, rather than considering it as a failure. Although the needling rates were not correlated to the bleb characteristics at month 6, the correlation would change if they were followed up for 12 months or more, resulting in a consequent change in bleb distribution. Bleb morphology follows a natural course over time in trabeculectomy or glaucoma drainage device blebs, as found in previous studies.[19–21] Lenzhofer et al.[5] reported that the proportion of subconjunctival separation type was highest in the first week and decreased continuously in the course of bleb

Downloaded from hwmaint.iovs.org on 04/23/2024

development over time in XEN blebs. The changeability of a filtering bleb could be not only temporal, but also be event wise (e.g., needling, discontinuation of steroid eye drops, or readministration of glaucoma eye drops), which might be a reason that the tip location was not directly linked to surgical success in our study. Regardless of this perspective, it seems to be reasonable to exclude needling in our multivariate analysis of which the goal was to determine the early predictors for successful XEN bleb, because we generally perform needling at least 1 or 2 months postoperatively, when a filtering bleb might have developed to a certain degree.

Regarding safety profiles, the ECC and best-corrected visual acuity were checked postoperatively (ECC at months 1, 2, 3, and 6; best-corrected visual acuity at days 1 and 2, weeks 1 and 2, months 1, 2, 3, and 6). ECCs decreased in the qualified success, qualified failure, complete success, and complete failure groups by 4.7%, 7.8%, 3.8%, and 8.1%, respectively, in our study. Given that Lass et al.[22] described that ECCs decreased by 9.6% and 8.9% after a suprachoroidal microstent and cataract surgery only at month 6, respectively, our results showed that the adverse effect of XEN implantation on the corneal endothelium is minimal compared with that of routine cataract surgery. The best-corrected visual acuities of the four groups decreased the most on day 1, before slowly recovering to their preoperative levels after 2 months postoperatively, which were changes that were clearly linked to the features of IOP changes.

There is an additional point that could potentially be biased. The preoperative IOP in the intraconjunctival type on day 1 was higher than that in the other groups. It is not clear whether the intraconjunctival location of the XEN tip could be inversely affected by other variables, such as the baseline IOP. However, the delta changes in IOP from baseline to week 1 postoperatively were statistically different in between intraconjunctival type and others (-31.83 ± 13.20 mm Hg vs. -18.64 ± 7.80 mm Hg; $P = 0.020$), although the ratio of the decrement between the two groups did not reach statistical difference ($68.2 \pm 13.4\%$ vs. $75.9 \pm 15.2\%$; $P = 0.174$). This finding could imply that, by all means, the success rates might be insufficient to represent the pros of interventions over controls if we are focused on the delta changes in IOP after certain anti-glaucoma interventions.

Interestingly, we found that 7 of the 31 patients showed a rather unexpected bleb morphology on day 1, which we decided to name uviform bleb because there were numerous round-shaped protuberances covering the inner bleb wall. To the best of our knowledge, this report is the first to describe an early bleb morphology after XEN implantation that has unique features in terms of its moderate association with PXG ($n = 10$; Cohen's kappa $= 0.439$; $P = 0.022$). We speculate that these protuberances were found by the benefit of the minimal invasiveness of the XEN procedure, whereas traditional filtering surgeries such as trabeculectomy almost always disrupt the subconjunctival space and transform it into totally different limbal conjunctival geographies. Want et al.[23] reported that fibroblasts of pseudoexfoliation syndrome displayed significantly decreased autophagic flux rates, indicating a decreased clearance of autophagosomes. A diminished capacity for degradation of denatured protein may have generated the protuberances in the XEN blebs; however, two of the seven patients with uviform blebs did not have typical pseudoexfoliation materials on the pupil, which could be explained by a couple of hypothetical reasons. First, they might have subclinical signs that could not be detected with the slit-lamp examination. Some pseudophakic eyes with mild PXG are fastidious to detect and may have been overlooked. Second, the tube tips might have been deployed right in the middle of the lumen of conjunctival lymphatics. In this case, the round materials may reflect the cross-sections of the luminal raphes inside the conjunctival lymphatics or debris created during XEN implantation. Because the creation of cystic blebs can possibly be explained via this theory, the number of the implantations actually happened in this way could be more than two if the theory would be applied to other types of blebs.

In conclusion, our data suggest a possible link between XEN location in the early phase and better IOP control at postoperative month 6. Based on our analyses, an intraconjunctival and intratenon location of the XEN tip can affect the distribution of bleb morphology (a higher rate of avascular bleb or sparse wall), which is more likely to have better IOP control at month 6, although it was not directly related to surgical success. The uviform type was more likely to become no or low wall after 6 months. Additionally, female sex and a lower IOP at week 1 postoperatively indicated a greater probability of successful XEN bleb in the first 6 months. Our findings can help to identify techniques and patients that are more favorable to early surgical success of the XEN procedure by igniting a functioning bleb. Further evaluation in a long-term result would help back our study.

Acknowledgments

The authors thank Sohyeon Lee for her excellent support in data management in this study.

Downloaded from hwmaint.iovs.org on 04/23/2024

Author Contributions

Conceptualization and design of the study (S.R.), collection and management of data (Y.K.), analysis and interpretation of data (Y.K., S.L., S.R.), writing of the article (Y.K., S.R.), approval of manuscript (Y.K., S.L., S.R.)

Disclosure: **Y. Kim,** None; **S.-H. Lim,** None; **S. Rho,** None

References

1. Gedde SJ, Schiffman JC, Feuer WJ, Herndon LW, Brandt JD, Budenz DL, et al. Treatment outcomes in the Tube Versus Trabeculectomy (TVT) study after five years of follow-up. *Am J Ophthalmol*. 2012;153(5):789–803.e2.
2. Yang SA, Mitchell W, Hall N, Elze T, Lorch AC, Miller JW, et al. Trends and usage patterns of minimally invasive glaucoma surgery in the United States: IRIS(R) registry analysis 2013-2018. *Ophthalmol Glaucoma*. 2021;4(6):558–568.
3. Schlenker MB, Gulamhusein H, Conrad-Hengerer I, Somers A, Lenzhofer M, Stalmans I, et al. Efficacy, safety, and risk factors for failure of standalone ab interno gelatin microstent implantation versus standalone trabeculectomy. *Ophthalmology*. 2017;124(11):1579–1588.
4. Yu DY, Morgan WH, Sun X, Su EN, Cringle SJ, Yu PK, et al. The critical role of the conjunctiva in glaucoma filtration surgery. *Prog Retin Eye Res*. 2009;28(5):303–328.
5. Lenzhofer M, Strohmaier C, Hohensinn M, Hitzl W, Sperl P, Gerner M, et al. Longitudinal bleb morphology in anterior segment OCT after minimally invasive transscleral ab interno Glaucoma Gel Microstent implantation. *Acta Ophthalmol*. 2019;97(2):e231–e237.
6. Sacchi M, Agnifili L, Brescia L, Oddone F, Villani E, Nucci P, et al. Structural imaging of conjunctival filtering blebs in XEN gel implantation and trabeculectomy: a confocal and anterior segment optical coherence tomography study. *Graefes Arch Clin Exp Ophthalmol*. 2020;258(8):1763–1770.
7. Rho S, Sung Y, Ma KT, Rho SH, Kim CY. Bleb analysis and short-term results of biodegradable collagen matrix-augmented Ahmed glaucoma valve implantation: 6-Month follow-up. *Invest Ophthalmol Vis Sci*. 2015;56(10):5896–5903.
8. Song M, Lee S, Choe D, Kim S, Roh YH, Rho S. Clinical and biological evaluations of biodegradable collagen matrices for glaucoma drainage device implantation. *Invest Ophthalmol Vis Sci*. 2017;58(12):5329–5335.
9. Dunn OJ. Multiple comparisons among means. *J Am Stat Assoc*. 1961;56:52–64.
10. Cohen J. A coefficient of agreement for nominal scales. *Edu Pschol Meas*. 1960;20(1):37–46.
11. Okimoto S, Kiuchi Y, Akita T, Tanaka J. Using the early postoperative intraocular pressure to predict pressure control after a trabeculectomy. *J Glaucoma*. 2014;23(6):410–414.
12. Lim SC, S.C. Long-term outcomes of mitomycin-c trabeculectomy in exfoliative glaucoma versus primary open-angle glaucoma. *J Glaucoma*. 2017;26(4):303–310.
13. Teus MA, Paz Moreno-Arrones J, Castano B, Castejon MA, Bolivar G. Optical coherence tomography analysis of filtering blebs after long-term, functioning trabeculectomy and XEN(R) stent implant. *Graefes Arch Clin Exp Ophthalmol*. 2019;257(5):1005–1011.
14. Jampel HD. Effect of brief exposure to mitomycin C on viability and proliferation of cultured human Tenon's capsule fibroblasts. *Ophthalmology*. 1992;99(9):1471–1476.
15. Seol BR, Lee SY, Kim YJ, Kim YK, Jeoung JW, Park KH. Comparison of the efficacy and safety of trabeculectomy with mitomycin C according to concentration: A prospective randomized clinical trial. *J Clin Med*. 2020;10(1):59.
16. Park HL, Kim JH, Jung Y, Park CK. Racial Differences in the extracellular matrix and histone acetylation of the lamina cribrosa and peripapillary sclera. *Invest Ophthalmol Vis Sci*. 2017;58(10):4143–4154.
17. Cutolo CA, Iester M, Bagnis A, Bonzano C, Negri L, Olivari S, et al. Early postoperative intraocular pressure is associated with better pressure control after XEN implantation. *J Glaucoma*. 2020;29(6):456–460.
18. Lenzhofer M, Strohmaier C, Sperl P, Hohensinn M, Hitzl W, Steiner V, et al. Effect of the outer stent position on efficacy after minimally invasive transscleral glaucoma gel stent implantation. *Acta Ophthalmol*. 2019;97(8):e1105–e1111.
19. Dempster AG, Molteno AC, Bevin TH, Thompson AM. Otago glaucoma surgery outcome study: electron microscopy of capsules around Molteno implants. *Invest Ophthalmol Vis Sci*. 2011;52(11):8300–8309.
20. Molteno AC, Bevin TH, Dempster AG, Sarris M, McCluskey P. Otago Glaucoma Surgery Outcome Study: cytology and immunohistochemistry of trabeculectomy blebs. *Invest Ophthalmol Vis Sci*. 2013;54(7):4991–4999.

Downloaded from hwmaint.iovs.org on 04/23/2024

21. Molteno ACB, Devereux F. Otago glaucoma surgery outcome study: further histology an immunohistochemistry of Molteno implant blebs. *Invest Ophthalmol Vis Sci*. 2015;56:4364–4374.
22. Lass JH, Benetz BA, He J, Hamilton C, Von Tress M, Dickerson J, et al. Corneal endothelial cell loss and morphometric changes 5 years after phacoemulsification with or without CyPass microstent. *Am J Ophthalmol*. 2019;208:211–218.
23. Want A, Gillespie SR, Wang Z, Gordon R, Iomini C, Ritch R, et al. Autophagy and mitochondrial dysfunction in tenon fibroblasts from exfoliation glaucoma patients. *PLoS One*. 2016;11(7):e0157404.

Downloaded from hwmaint.iovs.org on 04/23/2024